

## Left Temporal Lobe Arachnoid Cyst Presenting with Symptoms of Psychosis

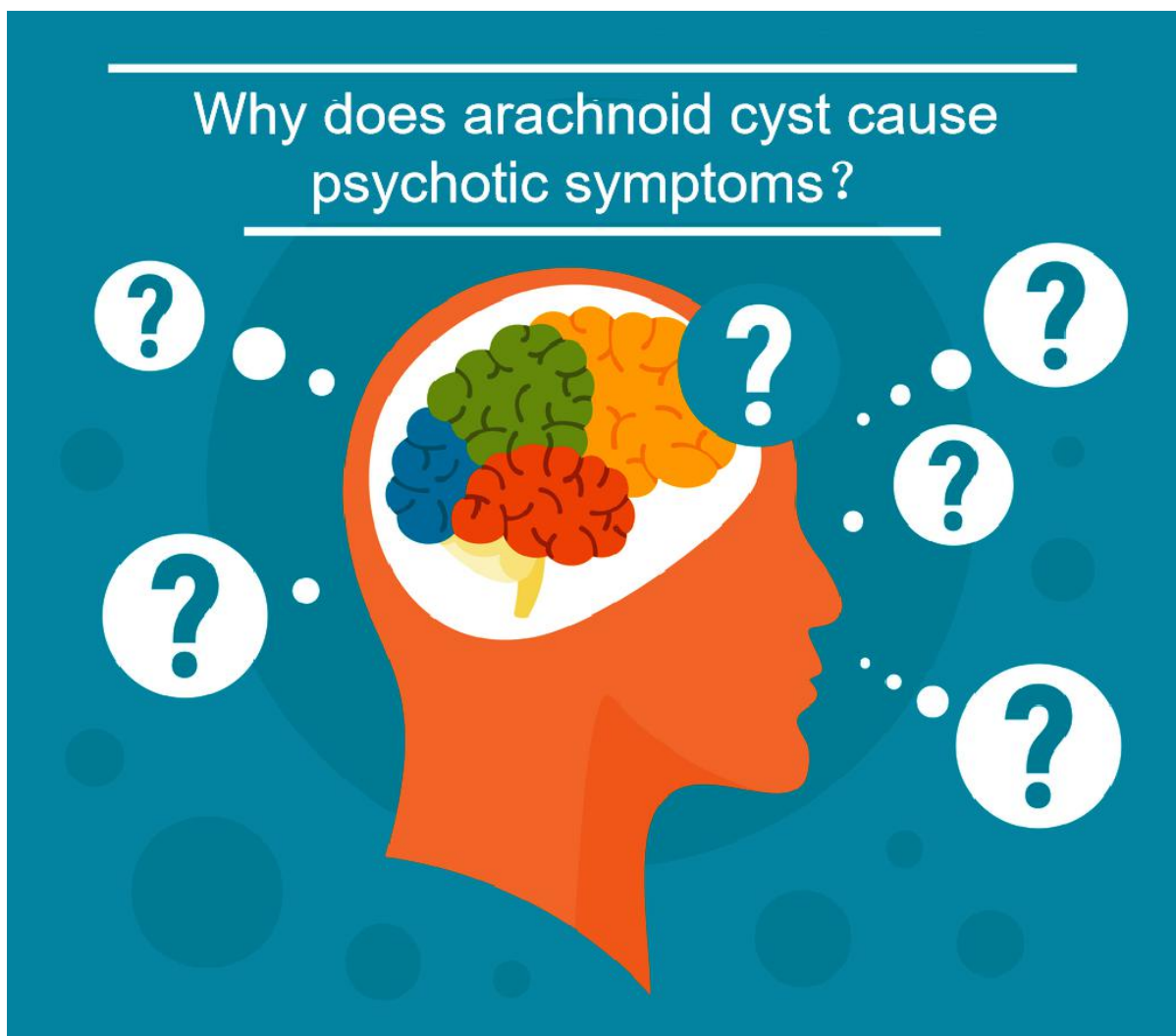
Javed Ather Siddiqui<sup>1,4\*</sup>, Shazia Farheen Qureshi<sup>2,4</sup>, Abdullah Alzahrani<sup>3</sup>

<sup>1</sup>Department of Psychiatry, Seth Gordhandas Sunderdas Medical College and the King Edward Memorial Hospital, Mumbai, India. <sup>2</sup>College of Physicians and Surgeons of Bombay, Mumbai, India. <sup>3</sup>Psychiatrist and head of department forensic psychiatry Mental Health Hospital, Taif, Saudi Arabia. <sup>4</sup>Psychiatrist, Department Psychiatry Mental Health Hospital, Taif, Saudi Arabia.

\*Corresponding to: Javed Ather Siddiqui, H.No. 2-10-93, B/6. Opposite super motar driving school, Harsh Nagar, AURNGABAD-431001 (Maharashtra), India. Email: javedsiddiqui2000@gmail.com.

### Highlights

This paper presents a case report of a 35-year-old man with left temporal lobe arachnoid cyst, characterized by the insidious onset of psychotic symptoms of varying intensity and explores the possible etiologic relationship between an arachnoid cyst, and his psychotic symptoms.



**Abstract**

Arachnoid cysts are uncommon benign neurological tumors, and having presentation like schizophrenia, which has been reported in association with this cyst. The presence of psychiatric disturbances of arachnoid cyst has not been clearly mentioned in the literature. Even though, the appearance of some of the references that focuses on a possible link between arachnoid cysts and psychotic symptoms. Here we present a case report of a 35-year-old man, characterized by the insidious onset of psychotic symptoms of varying intensity such as multiple physical assaults on people with stone. Due to organic suspicion one cannot exclude the possibility that the lesion played a significant role in this psychiatric presentation.

**Keywords:** Arachnoid cyst, Left temporal lobe, Psychosis

---

**Authors' contributions**

Javed Ather Siddiqui and Shazia Farheen Qureshi contributed to the acquisition data and manuscript writing. Abdullah Alzahrani assisted with data acquisition and revised the manuscript.

**Competing interests:**

No competing interest

**Citation:**

Javed Ather Siddiqui, Shazia Farheen Qureshi, Abdullah Alzahrani. Left Temporal Lobe Arachnoid Cyst Presenting with Symptoms of Psychosis. Psychosomatic Medicine Research. 2021; 3(4): 196-199.

**Executive Editor:** Cui-Hong Zhu.

**Submitted:** 7 July 2021, **Accepted:** 4 October 2021, **Online:** 15 November 2021.

## Introduction

Arachnoid cyst is congenital benign space-occupying lesions containing cerebrospinal fluid. It may produce severe structural changes in brain; these changes may result in cognitive deficits and atypical psychiatric symptoms. It may or may not produce symptoms, if symptomatic may present with headache, seizure, focal neurological deficit, and signs and symptoms of an increase intracranial pressure [1]. Many articles have been reported that patients with intracranial arachnoid cysts presented with psychiatric illness as their main symptom [2]. Even though no clear mechanism has yet been identified, there are many examples of patients being cured of their psychiatric symptoms following neurosurgical intervention [3].

## Case Report

A 35 years old Saudi single man, by occupation soldier was admitted at our forensic psychiatric ward for his crime, as he killed an old man. He presented with history of disturbed behavior since two years but increased for one month such as suspiciousness, disorganized behavior, not interacting, neglecting himself and muttering to self.

During mental status examination, patient is confused with incoherent speech, anxious and fearful, and his affect was restricted. He had delusions of guilt, and persecution. There were no suicidal or homicidal ideas, and no hallucinations reported. He had lack of insight and impaired judgment. He had history of multiple bouts of physical assault with the stone on father, other family member and his officer. Furthermore, he has history of road traffic accident two years back with neurological deficit for two months, unable to walk then become disorganized and neglecting himself.

There is no history of substance abuse and no history suggesting medical and surgical intervention. Physical and neurological examinations were normal. No family history of mental illness. All routine blood examinations including complete blood cell count, liver and kidney functions and serum electrolytes were within normal limit. Electroencephalogram was done it showed no seizure activity, so this cyst is not focus of epileptic seizure. Computed tomography scan was done it shows left temporal extra axial CSF density with mild compression on temporal lobe likely arachnoid cyst, depicted in figure 1 and 2. Patient was referred to neurosurgery consultation, due to lack of neurological symptoms they discharged and advised the medical management if needed. Patient was started on haloperidol tablet 10 mg per day along with valproic acid 1000 mg per day, patient showed remarkable improvement, but never reached baseline

still he is socially isolated and having scanty induced speech.

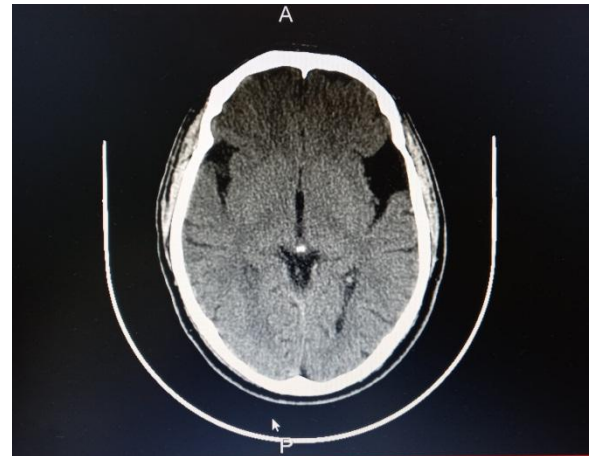

Figure 1: Computed Tomography Scan of the brain without contrast showing Arachnoid cyst at left temporal lobe.

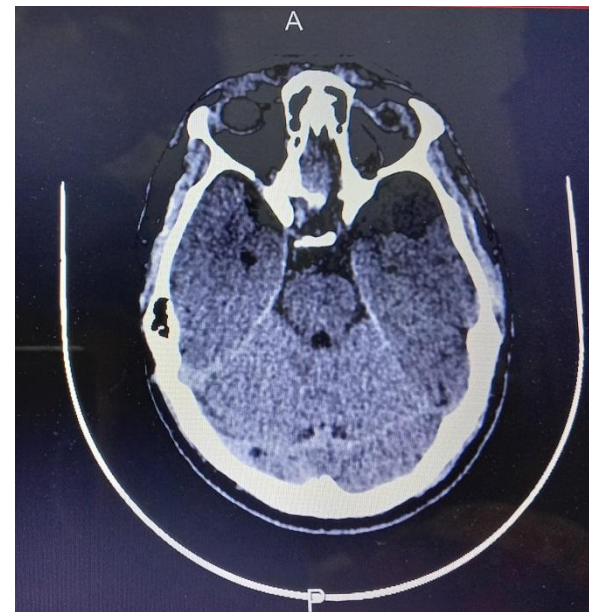

Figure 2: Axial view of Computed Tomography Scan of Arachnoid cyst seen at left temporal lobe.

## Discussion

In our patient mild to moderate improvement of his symptoms was seen, but he never reached baseline. He used to attack most of the people with stone, so this patient's behavior raised increased suspicion of an organic etiology of his illness. There is a possibility that patient's brain lesion precipitated psychiatric symptoms, so we concluded that patient's abnormal behavior is most likely secondary to arachnoid cyst because he has on and off physical assault with stones on many people, and has never reached baseline. This

Submit a manuscript: <https://www.tmrjournals.com/psmr>



case report explores the possible etiologic relationship between an arachnoid cyst, and his psychotic symptoms. However, neurosurgical consultation concluded that the patient's psychiatric symptoms were not related to arachnoid cyst, also the literature says that evidence of improvement and resolution of psychosis after neurosurgical intervention such as removal of an arachnoid cyst, and they also said that conservative management was the most frequent adopted options.

In our patient arachnoid cyst seen in the left temporal lobe, and there is some relation between the abnormality in this area and presence of psychotic symptoms [4]. Some studies show that psychotic symptoms mostly seen 76 the percent of patients who's the temporal lobe is being affected [5]. We also observed that our patient improved partially and slowly with medications because, in the literature said that the patient with arachnoid cyst associated with the psychosis will not get the complete remission of psychotic symptoms unless surgical intervention of arachnoid cyst is not done [6, 7] but the rapid improvement was seen when the surgical intervention was performed [8, 9]. Such interventions are the craniotomy, drainage or the excision [10]. Schizophrenia like psychosis associated with an arachnoid cyst which mainly affects with temporal lobe which is seen in our case.

Even though there is no clear cut mechanism has yet identified, but many cases being cured after the neurological interventions. Structural changes of the brain due to the compressed the left temporal lobe such as space-occupying lesions, biochemical changes, organ failures, infections, and nutritional deficiencies are the causes of psychosis that are secondary to general medical conditions. Some researcher also believe that most of the cases of cysts with psychosis are developmental malformations that arise from splitting of tearing of temporal lobe. The changes in the neurophysiological, and neuropsychological tests are also contributing factors that causes an etiologic relationship between cyst and psychosis [11]. According to medical literature, causes of the cyst have run in families suggesting that a genetic predisposition may play a role in development of psychosis with cyst. In the future, need to progression of modern imaging techniques, and psychiatrist should find out structural brain abnormalities, which gets more ideas of relationship between cysts with psychosis. There are more correct diagnostic tools, and techniques which merge clinical manifestations and structural findings should be developed to increase the diagnostic reliability and validity. Also in future to look for and rule out the organicity, and to establish the temporal relationship between the same so therapeutic interventions can be modified.

## Conclusion

We concluded that abnormal behavior of the patient was associated with an arachnoid cyst. Arachnoid cyst compressed the left temporal lobe, and related structure that is occurrence of psychotic symptoms.

## References

1. Greenbreg M. Developmental Anomalies-Arachnoid Cyst. Handbook Of Neurosurgery: 7th Eds. New York; Thieme press 2010.
2. Bahk WM, Pae CU, Chae JH, et al. A case of brief psychosis associated with an arachnoid cyst. *Psychiat Clin Neuros*. 2002; 56:203-205.
3. Wong CW, Ko SF, Wai YY, et al. Arachnoid cyst of the lateral ventricle manifesting positional psychosis. *Neurosurgery*. 1993; 32: 841-843.
4. Shenton ME, Kikinis R, Jolesz FA, et al. Abnormalities of the left temporal lobe and thought disorder in schizophrenia: a quantitative magnetic resonance imaging study. *N Engl J Med*. 1992;327:604-612.
5. Soniat TL. Psychiatric symptoms associated with intracranial neoplasms. *Am J Psychiatry*. 1951;108:19-22
6. da Silva JA, Alves A, Talina M, et al. Arachnoid cyst in a patient with psychosis: Case report. *Ann Gen Psychiatry*. 2007; 6:16.
7. Kuloglu M, Caykoylu A, Yilmaz E, et al. A left temporal lobe arachnoid cyst in a patient with schizophrenia-like psychosis: a case report. *Prog Neuropsychopharmacol Biol Psychiatry*. 2008; 32:1353-1354.
8. Baquero GA, Molero P, Pla J, et al. A schizophrenia-like psychotic disorder secondary to an arachnoid cyst remitted with neurosurgical treatment of the cyst. *Open Neuroimag J*. 2014;8:1.
9. Colameco S, DiTomasso RA. Arachnoid cyst associated with psychological disturbance. *New J Med*. 1982; 79:209-210.
10. Kuhnley EJ, White DH, Granoff AL. Psychiatric presentation of an arachnoid cyst. *J Clin Psychiatry*. 1981; 42:167-168.
11. Kohn R, Lilly RB, Sokol MS, et al. Psychiatric presentations of intracranial cysts. *J Neuropsychiatry Clin Neurosci*. 1989; 1: 60-66.

