

Regional resting state perfusion variability and delayed cerebrovascular uniform reactivity in subjects with chronic carotid artery stenosis

Arkadiusz Szarmach¹, Mariusz Kaszubowski², Agnieszka Sabisz¹, Andrzej F. Frydrychowski³, Grzegorz Halena⁴, Maciej Piskunowicz⁵, Jarosław Dzierzanowski⁶, Michał Studniarek^{5,7}, Edyta Szurowska¹ and Paweł J. Winklewski^{1,3,8}✉

¹2nd Department of Radiology, Medical University of Gdansk, Gdańsk, Poland; ²Department of Economic Sciences, Faculty of Management and Economics, Gdansk University of Technology, Gdańsk, Poland; ³Department of Human Physiology, Medical University of Gdansk, Gdańsk, Poland; ⁴Department of Cardiovascular Surgery, Medical University of Gdansk, Gdańsk, Poland; ⁵1st Department of Radiology, Medical University of Gdansk, Gdańsk, Poland; ⁶Department of Neurosurgery, Medical University of Gdansk, Gdańsk, Poland; ⁷Department of Diagnostic Imaging, Medical University of Warsaw, Warsaw, Poland; ⁸Faculty of Health Sciences, Pomeranian University of Słupsk, Słupsk, Poland

The aim of this study was to assess regional perfusion at baseline and regional cerebrovascular resistance (CVR) to delayed acetazolamide challenge in subjects with chronic carotid artery stenosis. Sixteen patients (ten males) aged 70.94 ± 7.71 with carotid artery stenosis $\geq 90\%$ on the ipsilateral side and $\leq 50\%$ on the contralateral side were enrolled into the study. In all patients, two computed tomography perfusion examinations were carried out; the first was performed before acetazolamide administration and the second 60 minutes after injection. The differences between mean values were examined by paired two-sample t-test and alternative nonparametric Wilcoxon's test. Normality assumption was examined using W Shapiro-Wilk test. The lowest resting-state cerebral blood flow (CBF) was observed in white matter (ipsilateral side: 18.4 ± 6.2 ; contralateral side: 19.3 ± 6.6) and brainstem (ipsilateral side: 27.8 ± 8.5 ; contralateral side: 29.1 ± 10.8). Grey matter (cerebral cortex) resting state CBF was below the normal value for subjects of this age: frontal lobe – ipsilateral side: 30.4 ± 7.0 , contralateral side: 33.7 ± 7.1 ; parietal lobe – ipsilateral side: 36.4 ± 11.3 , contralateral side: 42.7 ± 9.9 ; temporal lobe – ipsilateral side: 32.5 ± 8.6 , contralateral side: 39.4 ± 10.8 ; occipital lobe – ipsilateral side: 24.0 ± 6.0 , contralateral side: 26.4 ± 6.6). The highest resting state CBF was observed in the insula (ipsilateral side: 49.2 ± 17.4 ; contralateral side: 55.3 ± 18.4). A relatively high resting state CBF was also recorded in the thalamus (ipsilateral side: 39.7 ± 16.9 ; contralateral side: 41.7 ± 14.1) and cerebellum (ipsilateral side: 41.4 ± 12.2 ; contralateral side: 38.1 ± 11.3). The highest CVR was observed in temporal lobe cortex (ipsilateral side: $+27.1\%$; contralateral side: $+26.1\%$) and cerebellum (ipsilateral side: $+27.0\%$; contralateral side: $+34.6\%$). The lowest CVR was recorded in brain stem (ipsilateral side: $+20.2\%$; contralateral side: $+22.2\%$) and white matter (ipsilateral side: $+18.1\%$; contralateral side: $+18.3\%$). All CBF values were provided in milliliters of blood per minute per 100 g of brain tissue (ml/100g/min). Resting state circulation in subjects with carotid artery stenosis is low in all analysed structures with the exception of insula and cerebellum. Acetazolamide challenge yields relatively uniform response in both hemispheres in the investigated population. Grey matter is more reactive to acetazolamide challenge than white matter or brainstem.

Key words: chronic carotid artery stenosis, computed tomography perfusion, acetazolamide test, cerebral blood flow, cerebral blood volume, mean transit time, time to peak

Received: 27 February, 2018; revised: 28 February, 2018; accepted: 28 February, 2018; available on-line: 12 March, 2018

✉ e-mail: pawelwinklewski@wp.pl

Abbreviations: ASL, arterial, spin labeling; CBF, cerebral blood flow; CBV, cerebral blood volume; CCA, common carotid artery; CTP, computed tomography perfusion; CVR, cerebrovascular reactivity; DSA, digital subtraction angiography; ECA, external carotid artery; EDV, end diastolic velocity; LICA, left internal carotid artery; MTT, mean transit time; NASCET, The North American Symptomatic Carotid Endarterectomy Trial; NCCT, non, contrast computed tomography; PET, positron emission tomography; PSV, peak systolic velocity; RICA, right internal carotid artery; SPECT, single photon emission computed tomography; TTP, time to peak

Highlights

- Cerebral blood flow is low in resting state in frontal, parietal and temporal cortex grey matter in subjects with carotid artery stenosis
- A particularly low cerebral blood flow is evident in the occipital cortex
- High resting-state cerebral blood flow is observed in the insula and cerebellum
- Acetazolamide challenge yields relatively uniform response in both hemispheres in the analysed population

INTRODUCTION

Brain stroke is currently the second most common cause of death. It has been estimated that one in ten European people over 50 years of age and one in two over 70 dies for this reason (Wintermark *et al.*, 2002). Carotid artery surgery remains one of the therapeutic options for this patient population (MRC, 1991; NASCET, 1991). However, there is accumulating evidence that vascular stiffening, rather than carotid luminal narrowing, adversely influences cognitive aging and provides a potential target for ameliorating age-related cognitive decline (Wardlaw *et al.*, 2016). It is becoming clear that further improvement in outcomes for patients with carotid stenosis requires a better understanding of the pathophysiology of this disease (Abbot, 2016).

The population suffering from chronic carotid artery stenosis that we investigated represents an interest-

ing pathophysiological state. It is characterized by low global cerebral blood flow (CBF), low global cerebral blood volume (CBV) and lack of significant differences at baseline regarding mean transit time (MTT), CBF and CBV between the ipsilateral and contralateral hemisphere to stenosis (Frydrychowski *et al.*, 2013; Szarmach *et al.*, 2016; Szarmach *et al.*, 2017a,b). Thus, the subjects from the described population are most likely very close to blood supply breakdown leading to stroke. Nevertheless, they still present relatively well-compensated perfusion, although at the very low end of the acceptable range. This population has already been described regarding misery perfusion and reduced cerebral metabolism. However, data related to both the regional pattern of baseline perfusion and regional cerebrovascular reactivity (CVR) in these subjects is missing.

The acetazolamide test is the procedure of choice to investigate cerebrovascular resistance (CVR) in subjects with chronic artery stenosis (Vorstrup *et al.*, 1986; Murakami *et al.*, 2002; Hartkamp *et al.*, 2012). Acetazolamide is a reversible inhibitor of the enzyme carbonic anhydrase, and while the exact mechanism has yet to be unveiled, the vasodilatory effect on the brain vasculature is ascribed to carbonic acidosis (Vorstrup *et al.*, 1984). Vasodilatory change in cerebral perfusion is usually measured 15 to 20 minutes before and after a challenge (Vorstrup *et al.*, 1986; Hokari *et al.*, 2008). However, the response to the acetazolamide test seems to be delayed in stenosed territories (Murakami *et al.*, 2002; Hartkamp *et al.*, 2012). One of our recent studies suggests that morphometric changes in the diameter of arteries originating from the circle of Willis are present even 60 minutes after the acetazolamide test (Szarmach *et al.*, 2017a). Therefore a delayed response to vasodilatory challenge appears to provide important pathophysiological information.

Thus the aim of this study was to assess regional perfusion with the use of CTP at baseline and regional CVR in response to delayed acetazolamide challenge in subjects with chronic carotid artery stenosis. We hypothesized that in the described population there is marked heterogeneity in spatial baseline perfusion and that the delayed acetazolamide test may unveil significant differences in CVR characteristics. In particular, we expected higher CBF in cortical and deep GM and lower CBF in WM. We speculated that WM and structures fed by the vertebrobasilar circulatory system might be characterized by a relatively low CVR.

MATERIAL AND METHODS

Patients. A total of 16 symptomatic patients (ten males) aged 70.94 ± 7.71 fulfilling the enrolment criteria were included into the study (Table 1). This study was carried out in accordance with the recommendations of Helsinki. The experimental protocol and the study were approved by the ethics committee of Medical University of Gdansk. All volunteers gave written informed consent to participate in the study.

The following inclusion criteria were defined:

1. age > 18 years,
2. written consent to participate in the study,
3. carotid artery stenosis $\geq 90\%$ on the ipsilateral side and $\leq 50\%$ on the contralateral side. The degree of internal carotid artery stenosis was assessed using Doppler ultrasonography examination and digital subtractive angiography (DSA) according to the method documented in the North American Symptomatic Carotid Endarterectomy Trial (NASCET, 1991),

4. complete circle of Willis and normal vertebral arteries (confirmed by DSA).

The following exclusion criteria were specified:

1. significant (> 70%) tandem stenosis,
2. intracranial tumours, aneurysm, vessel malformations,
3. total anterior cerebral infarct (TACI),
4. uncontrolled hyperthyroidism,
5. hypersensitivity to iodine or history of adverse effects following the administration of contrast agents,
6. stage II–V renal insufficiency were excluded from the study.

Angiography. Digital subtractive angiography was carried out before carotid artery stenting to confirm the degree of stenosis. Selective angiography of the target vessel was then performed to reveal the size of the carotid lesion, degree of stenosis, morphology of the internal carotid artery and its contribution to the circle of Willis.

Doppler ultrasound. Carotid arteries were examined with the patient in the supine position. The posterolateral transducer positions were used to examine the carotid arteries in the long and short axis. All the examinations were performed by the same operator and the same ultrasonography machine (Logiq S8, GE Healthcare) with a Doppler angle of 60° . On grey scale presence or absence and location of plaque were evaluated. On Doppler study peak systolic velocity (PSV) and end diastolic velocity (EDV) of common carotid artery (CCA), internal carotid artery (ICA) and external carotid artery (ECA) were evaluated. NASCET criteria were used for measuring the percentage of stenosis.

Computed tomography protocol. The imaging protocol consisted of Non-Contrast Computed Tomography (NCCT) and dynamic perfusion CT (CTP). In all subjects, CTP examinations were carried out twice: before and 60 minutes after an injection of 1.0 g Diamox i.v. (Mercury Pharmaceuticals, London, UK). All examinations were performed in transverse plane using a 64-MDct Light Speed VCT XT scanner (GE Healthcare Technologies, Chicago, Illinois, US).

Technical procedures. All subjects underwent non-enhanced plain brain CT scans (140 kV, 335 mAS, 0.9 second rotation time, number of images=56, total exposure time=6.3 s, and CDTIvol between 50 and 60 mGy) to exclude intracranial haemorrhage and distinguish between acute and old ischaemic stroke.

CPT studies were conducted on 40 mm thick transverse axial sections. A 40 mL bolus of non-ionic contrast media (Optiray 350 Mallinckrodt, St. Louis, Missouri, USA) was administered into an antecubital vein using a power injector (Dual Shot Alpha 7, Nemoto Kyorindo Co., Ltd, Japan) with an injection rate of 4 mL/s. After contrast injection, a bolus of 40 ml of physiological saline was administered. CT scanning was performed 5 seconds after the start of the injection with the following acquisition parameters: a sine mode series, 80 kV, 150 mAs, 5 mm slice thickness, 25-cm field-of-view, rotation time=1/s, number of images per rotation=8, cine time between images=0.5 s, image matrix=512x512, time interval between reconstructed images=0.5 s, interval=0 mm.

A total of 360 slices was obtained with a total scan time of 45 seconds. CDTIvol was approximately 390 mGy per examination. Scanning was performed at the level of the upper part of the cerebellum (over a distance of 40 mm), with the gantry angle set parallel to the orbitomeatal line to avoid direct exposure of the eye lens to radiation. For the second study in each patient,



Table 1 Subjects population.

| No. | Age | Gender | Degree and site of stenosis ICA | Cerebrovascular history | Concomitant diseases |
|-----|-----|--------|--|--|--|
| 1 | 70 | Male | LICA restenosis >90% | Previous left CAS, amaurosis fugax | Coronary artery disease, previous myocardial infarction, CABG and PTCA, hypertension, renal impairment |
| 2 | 69 | Male | RICA stenosis >95% | Recent stroke of the right hemisphere with transient contralateral hemiplegia, PACI | Hypertension |
| 3 | 80 | Female | RICA restenosis >90% | Previous RICA surgical CEA | Hypertension |
| 4 | 60 | Female | LICA occlusion | Recent stroke of the left hemisphere with transient brachio-facial hemiparesis, PACI | Hypertension, diabetes mellitus, coronary artery disease |
| 5 | 60 | Female | RICA stenosis >90% | Previous stent implantation for 99% stenosis in LICA | Hypertension, coronary artery disease, multiple myocardial infarctions in medical history |
| 6 | 58 | Male | RICA restenosis >90% | Previous RICA surgical CEA | Hypertension, dyslipidaemia, previous myocardial infarction, CABG and PTCA |
| 7 | 82 | Male | LICA stenosis >90% | Previous left subclavian artery revascularization with stent implantation, LACI | Hypertension, coronary artery disease, peripheral arterial disease, previous PTCA |
| 8 | 70 | Male | LICA stenosis >90% | Previous TIA, LACI | Hypertension, diabetes mellitus, coronary artery disease, previous myocardial infarction, PTCA, and lower limb endovascular and open revascularization |
| 9 | 70 | Female | LICA occlusion in intraoperative angiography | Previous TIA, amaurosis fugax | Hypertension, coronary artery disease, previous myocardial infarction |
| 10 | 71 | Male | RICA stenosis >95% | Previous LICA surgical CEA with subsequent carotid artery stenting | Hypertension, peripheral arterial disease, coronary artery disease, previous myocardial infarction |
| 11 | 59 | Female | LICA stenosis >90% | Previous TIA, LACI | Hypertension, diabetes mellitus |
| 12 | 71 | Male | LICA stenosis >95% | Previous RICA surgical CEA, amaurosis fugax | Hypertension, coronary artery disease, previous myocardial infarction, CABG and PTCA, previous peripheral vascular surgery |
| 13 | 66 | Male | LICA restenosis >95% | Ischaemic stroke of the left hemisphere with contralateral hemiparesis and aphasia. Previous surgical LICA CEA, PACI | Hypertension |
| 14 | 81 | Male | LICA stenosis >90% | Previous RICA surgical CEA, LACI | Hypertension, dyslipidaemia, coronary artery disease. Previous PTCA |
| 15 | 68 | Male | RICA stenosis >90% | Ischaemic stroke of the right hemisphere, PACI | Hypertension |
| 16 | 71 | Female | LICA stenosis >90% | Three strokes in the past with aphasia and transient right-sided plegia, PACI | Hypertension, diabetes mellitus, atrial fibrillation |

CABG, coronary artery bypass grafting; CAS, carotid artery stenting; CEA, carotid endarterectomy; LACI, lacunar anterior cerebral infarct; LICA, left internal carotid artery; PACI, partial anterior cerebral infarct; PTCA, percutaneous transluminal coronary angioplasty; RICA, right internal carotid artery; TIA, transient ischaemic attack.

the same general slice locations and identical technical parameters were used.

The assessment of perfusion parameters was carried out from the level of the upper part of cerebellum to the middle part of cerebral hemispheres included in the examination, in the area supplied by the middle, anterior and posterior cerebral artery.

Image post-processing. Post-processing was performed by two investigators twice in each case (before and after acetazolamide administration) using a dedicated diagnostic workstation (AW 4 GE Healthcare Technologies, Wisconsin, USA) equipped with a professional

post-processing software package to generate colour overlay maps of dynamic cerebral enhancement data (CT Perfusion version 4 (v 4.3.1), GE Healthcare Technologies, Wisconsin, USA). The readers were blinded to clinical and radiological information.

The standardized elliptical mirrored regions of interest (ROIs) were drawn manually. Each ROI (between 1 cm² to 4 cm² each) was determined at all analysed levels (Figs 1, 2 and SF1) in the region of the investigated structures. The large vessels, bones and cerebrospinal fluid were automatically excluded via brain perfusion software.



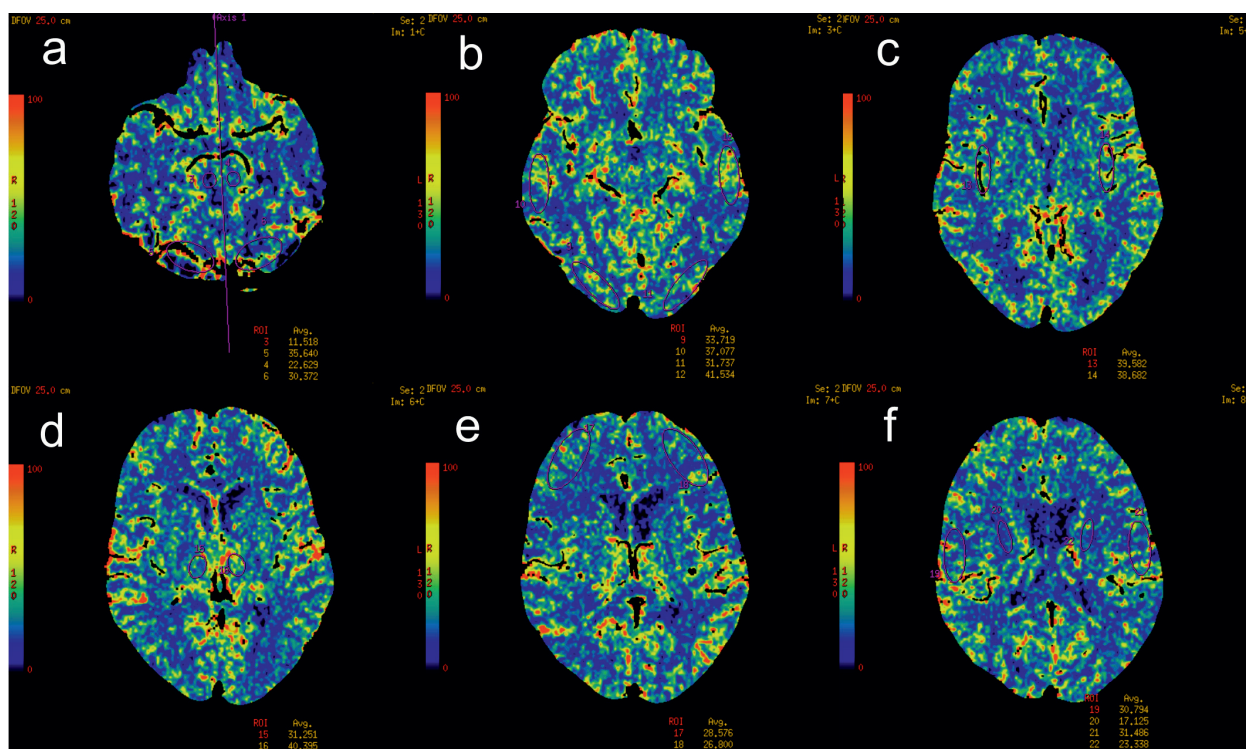


Figure 1. Pre-acetazolamide cerebral blood flow (CBF) CTP images in patient with severe right internal carotid artery (RICA) stenosis. Brainstem and cerebellum (a), occipital and temporal lobes (b), insula (c), thalamus (d), frontal lobe (e), parietal lobe and white matter of brain hemisphere (f).

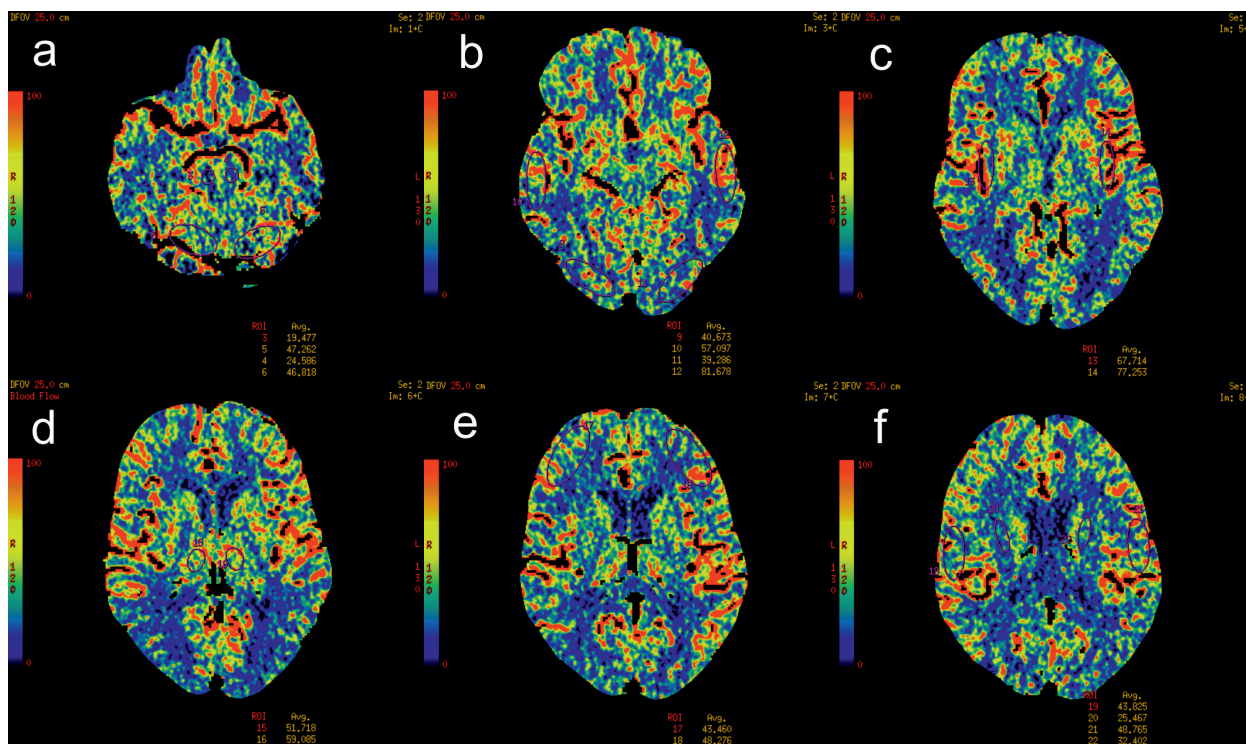


Figure 2. Post-acetazolamide cerebral blood flow (CBF) images in patient with severe right internal carotid artery (RICA) stenosis. After acetazolamide administration, there was a normal response (increase in CBF) to acetazolamide on the left side. The right hemisphere demonstrated "poorer" increase of CBF due to chronic impairment of cerebrovascular reactivity. Brainstem and cerebellum (a), occipital and temporal lobes (b), insula (c), thalamus (d), frontal lobe (e), parietal lobe and white matter of brain hemisphere (f).

Native scans are provided as supplementary Fig. SF1 at www.actabp.pl.

The “neuro brain stroke” mode was used for calculation of the perfusion metrics of Mean Transit Time (MTT), Cerebral Blood Flow (CBF), Cerebral Blood Volume (CBV), and Time to Peak (TTP) for brain stroke assessment using the maximal slope method.

Time-enhancement curves based on the passage of contrast material through the anterior cerebral artery and the superior sagittal sinus yielded the arterial input function (AIF) and the venous output function (VOF), respectively.

The MTT corresponds to the average time that red blood cells spend within a determinate volume of capillary MTT, computed and displayed in seconds.

The CBF is defined as the volume of blood passing through a given amount of brain tissue per unit of time, most commonly milliliters of blood per minute per 100 g of brain tissue (ml/100 g/min).

The CBV is calculated as the ratio of the area under the time-concentration curve for the first contrast material bolus passage through the tissue to the area under the curve for the VOF. The blood volume is the product of the blood flow and the mean transit time: $CBV = CBF \times MTT$.

The TTP is the time between the onset of the enhancement transient and the peak value of the time curve. Time-to-peak is computed and displayed in seconds, using the raw time curve data.

The absolute values of CT perfusion parameters (MTT, TTP, CBF, CBV) of one hemisphere in the region of anterior, middle and posterior cerebral artery distribution and contralateral mirroring areas in functional maps were measured.

Statistical analysis. To compare the results before and after acetazolamide challenge, differences in absolute CT values (MTT (s), CBV (ml/100 g), CBF (ml/100

g/min) and TTP (s)) and relative values (rMTT, rCBV, rCBF and rTTP – obtained as the ratio of appropriate values from ipsilateral side to contralateral side to stenosis) were analysed.

Raw data from all individual slices were presented as Mean \pm S.D and with Median value. Additionally, there were calculated the percentage changes of CT parameters by formula $(CT2 - CT1) / CT1 \times 100\%$ where CT1 and CT2 meant respectively CT values in the period before and after delayed acetazolamide test. Since the analysed groups were small ($N=16$) the differences between variables were examined at the same time by paired *t*-test and alternative nonparametric Wilcoxon's test. The *t*-test was stronger as it was the parametric test but in this case needed to be satisfied by the normality of paired differences. The W Shapiro-Wilk test revealed that not all of the samples fulfilled this assumption (results not presented). Therefore the best approach was to take into the consideration both tests results.

The level of significance was set at $\alpha=0.05$. All calculated *p*-values were for two-tailed tests. All raw data were analysed using the statistical software Statistica 12.5 (StatSoft, Tulsa, OK, USA).

RESULTS

Resting state CBF (ml/100 g/min), CBV (ml/100 g), MTT (s) and TTP (s) parameters and respective delayed changes in response to acetazolamide are presented in Figs 3–10. Detailed tabular results are provided in the supplementary section of the manuscript (ST1–ST9). All responses to acetazolamide test were statistically significant. There were no statistically significant differences between hemispheres.

The lowest resting state CBF was observed in white matter (ipsilateral side: 18.4 ± 6.2 ; contralateral side: 19.3 ± 6.6) and brainstem (ipsilateral side: 27.8 ± 8.5 ; con-

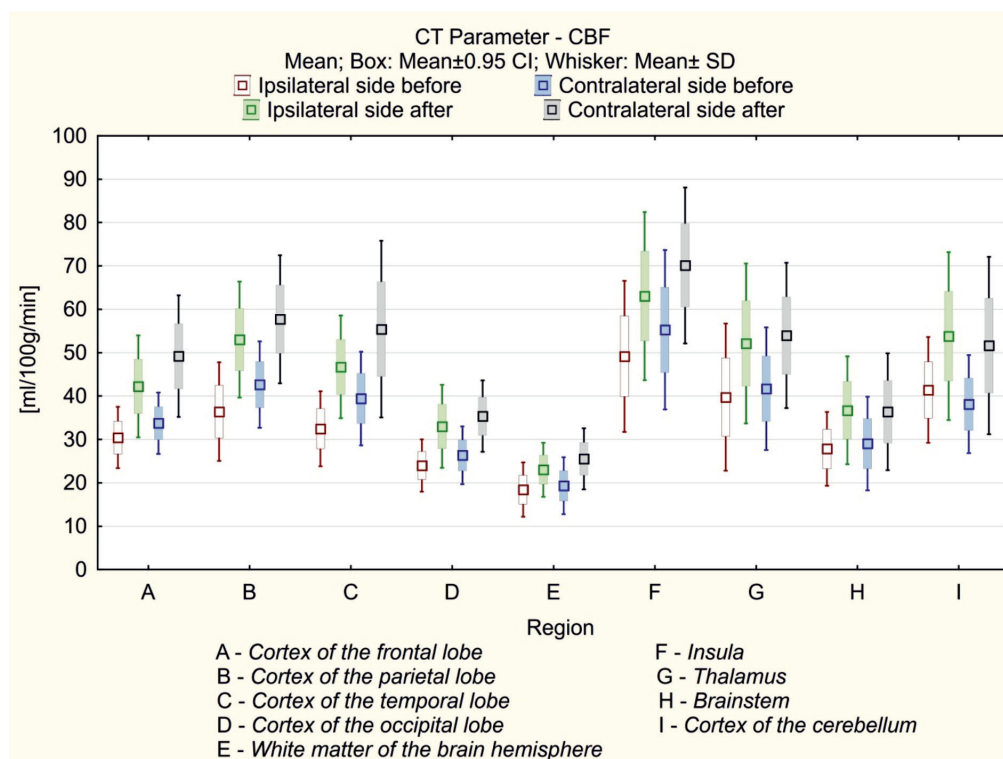


Figure 3. Resting state CBF and delayed CBF response to acetazolamide test in selected brain regions.

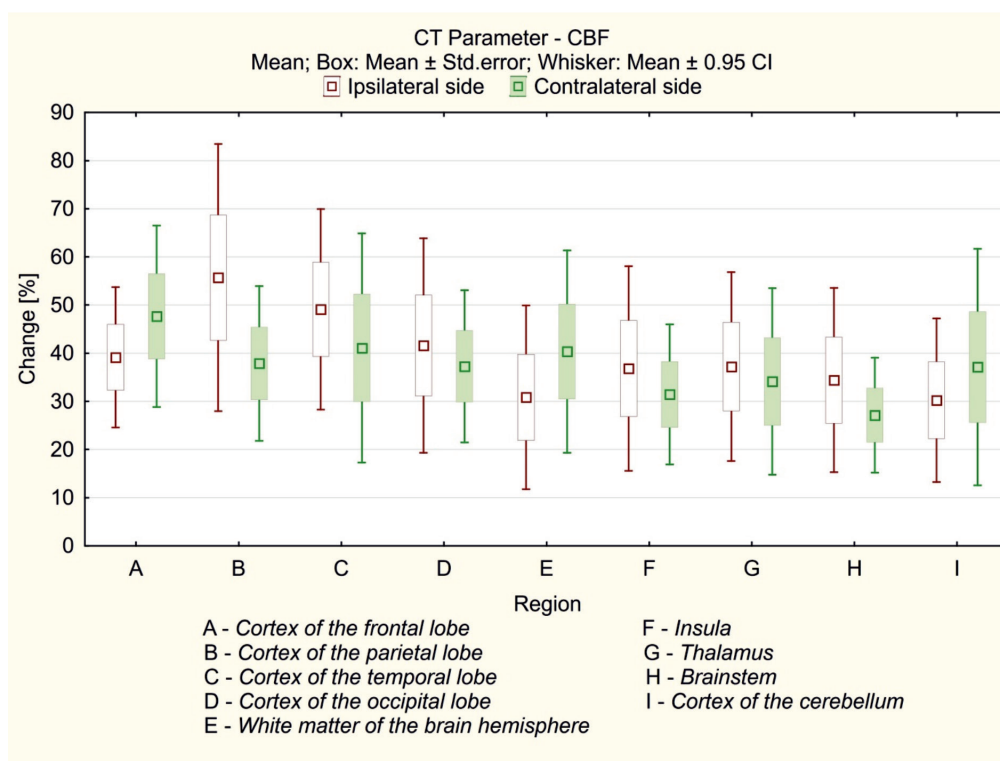


Figure 4. CBF response to delayed acetazolamide test.

tralateral side: 29.1 ± 10.8). Grey matter (cerebral cortex) resting state CBF was below the normal value for subjects of this age: frontal lobe – ipsilateral side: 30.4 ± 7.0 , contralateral side: 33.7 ± 7.1 ; parietal lobe – ipsilateral side: 36.4 ± 11.3 , contralateral side: 42.7 ± 9.9 ; temporal lobe – ipsilateral side: 32.5 ± 8.6 , contralateral side:

39.4 ± 10.8 ; occipital lobe – ipsilateral side: 24.0 ± 6.0 , contralateral side: 26.4 ± 6.6 .

The highest resting state CBF was observed in the insula (ipsilateral side: 49.2 ± 17.4 ; contralateral side: 55.3 ± 18.4). A relatively high resting state CBF was also recorded in the thalamus (ipsilateral side: 39.7 ± 16.9 ;

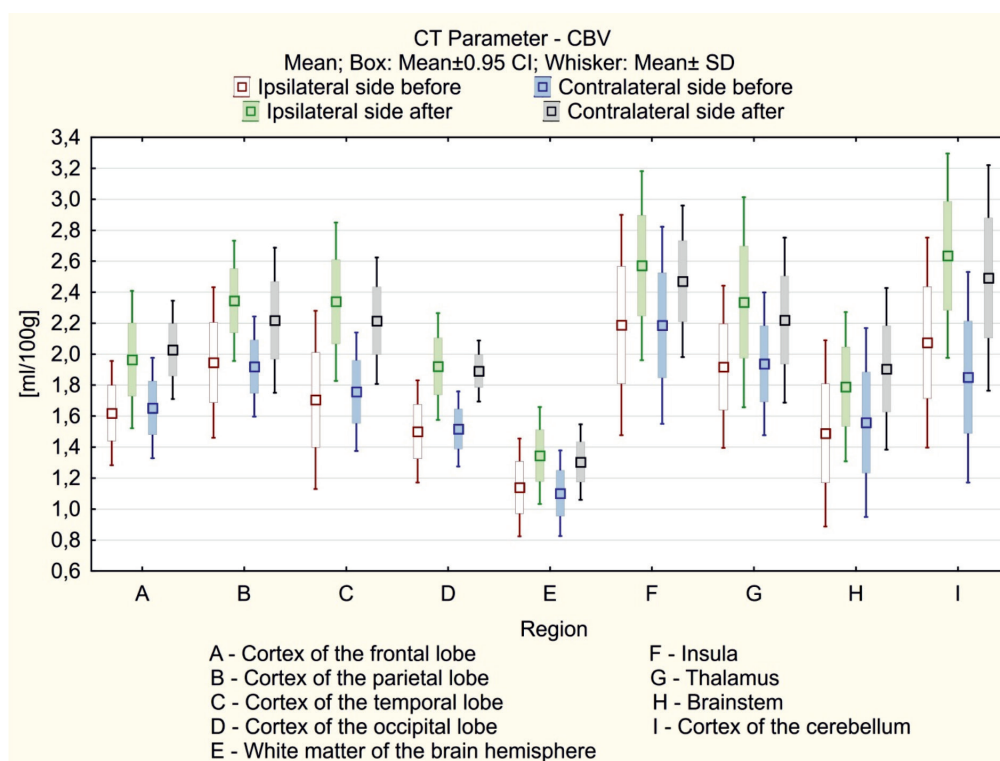


Figure 5. Resting state CBV and delayed response to acetazolamide test in selected brain regions.

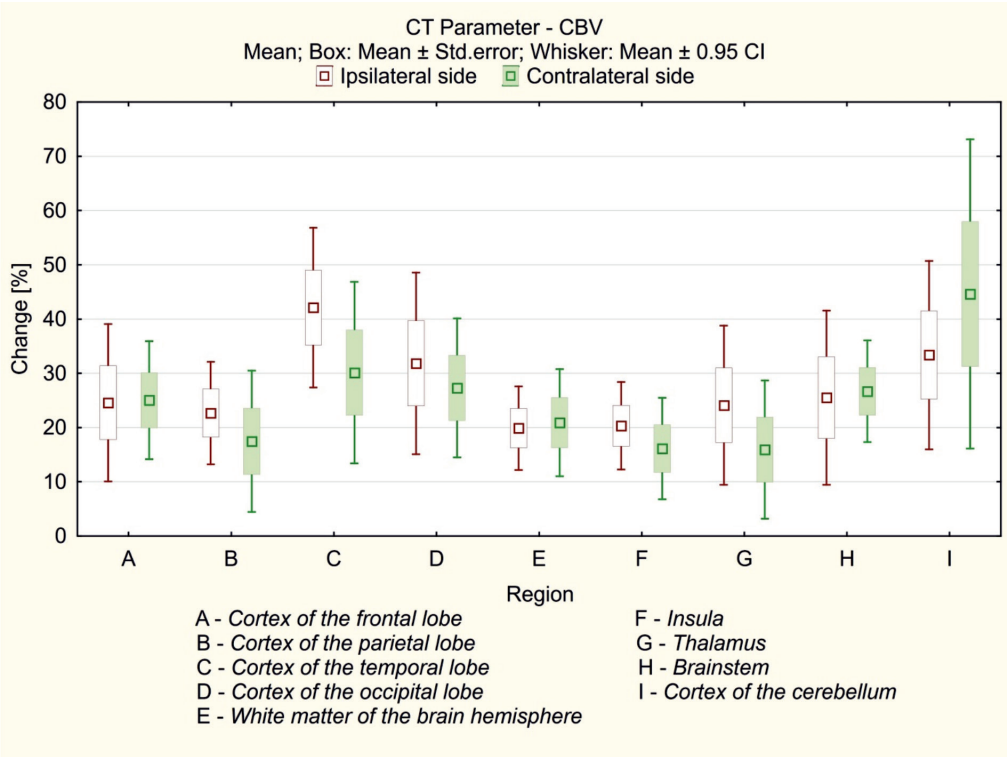


Figure 6. CBV response to delayed acetazolamide test.

contralateral side: 41.7 ± 14.1) and cerebellum (ipsilateral side: 41.4 ± 12.2 ; contralateral side: 38.1 ± 11.3).

Summing up, resting state CBF in subjects with carotid artery stenosis was low in all analysed structures with the exception of insula, thalamus and cerebellum. All

values were provided in millilitres of blood per minute per 100 g of brain tissue (ml/100 g/min).

The highest CVR in response to the acetazolamide test was observed in grey matter (cerebral cortex): frontal lobe – ipsilateral side: +38.8%, contralateral side:

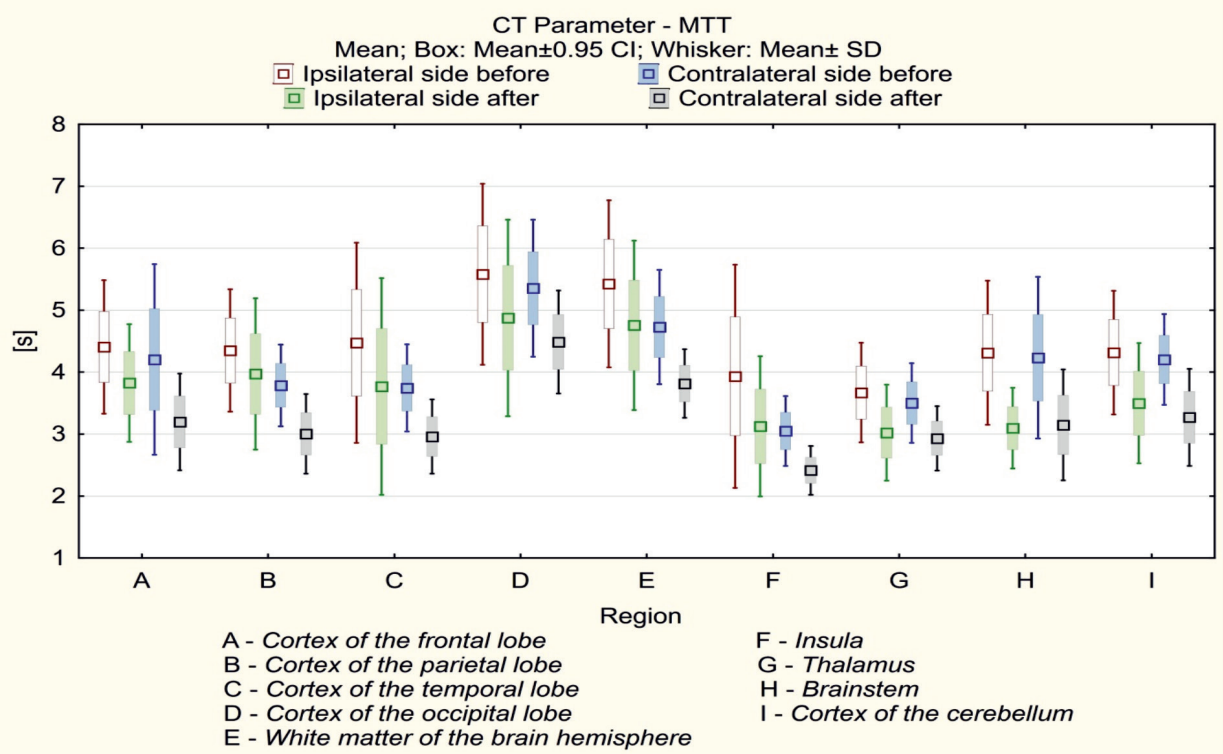


Figure 7. Resting state MTT and delayed response to acetazolamide test in selected brain regions.

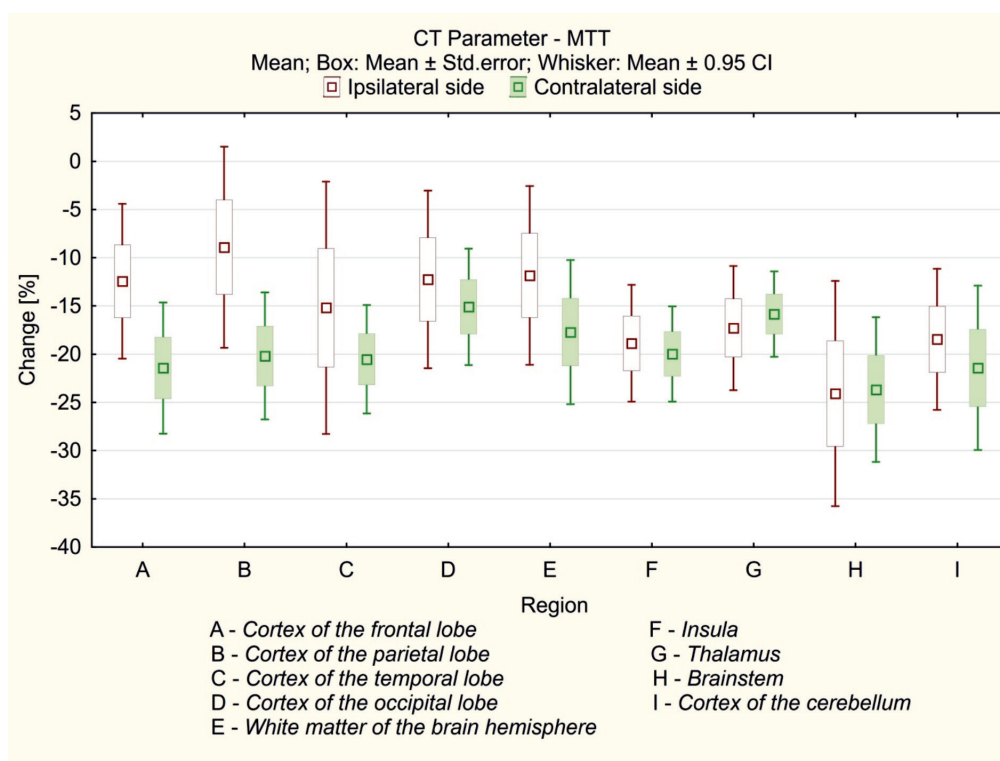


Figure 8. MTT response to delayed acetazolamide test.

+45.9%; parietal lobe – ipsilateral side: +45.6%, contralateral side: +34.7%; temporal lobe – ipsilateral side: +43.9%, contralateral side: +40.6%; occipital lobe – ipsilateral side: +37.6%, contralateral side: +34.13%. The lowest CVR was recorded in brainstem (ipsilateral side:

+30.8%, contralateral side: +25.2%) and white matter (ipsilateral side: +24.8%, contralateral side: +32.1%).

The lowest resting state CBV was observed in white matter (ipsilateral side: 1.14 ± 0.31 ; contralateral side: 1.10 ± 0.28), while in brainstem CBV was slightly higher (ipsilateral

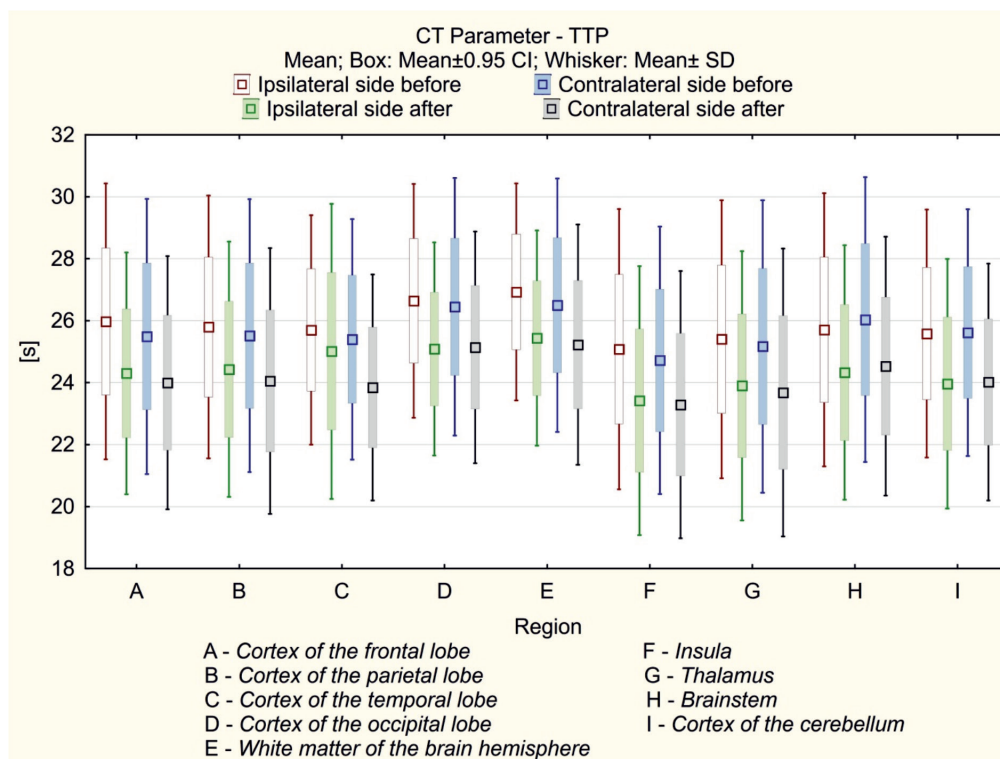


Figure 9. Resting state TTP and delayed response to acetazolamide test in selected brain regions.

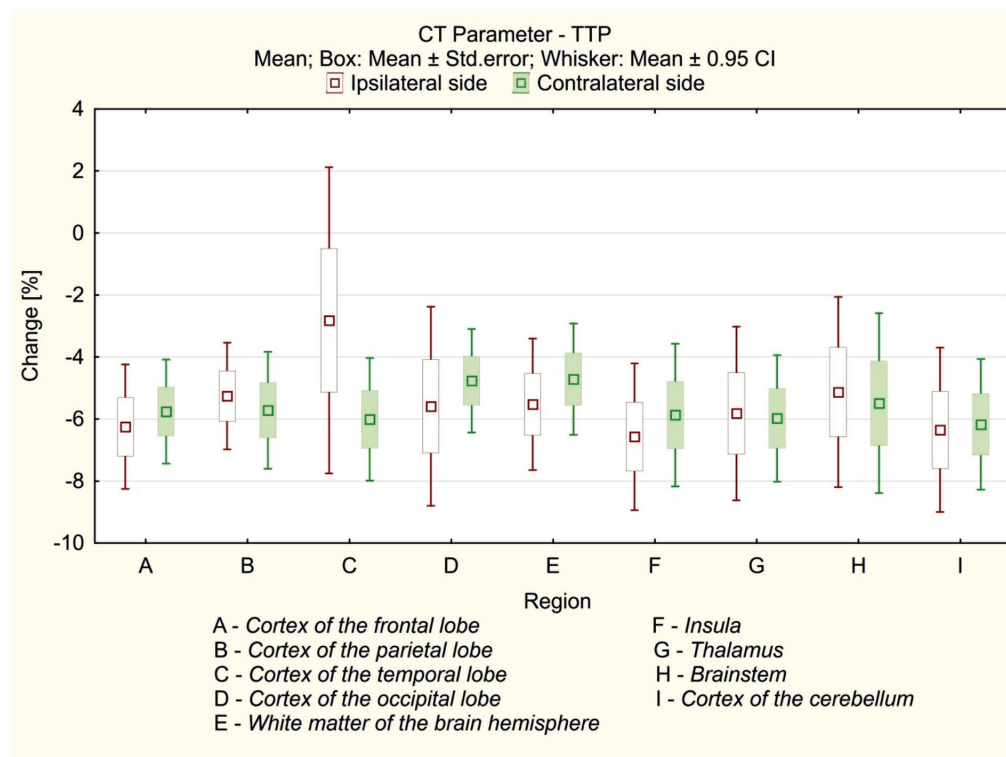


Figure 10. TTP response to delayed acetazolamide test.

side: 1.49 ± 0.60 ; contralateral side: 1.56 ± 0.61) and similar to occipital cortex (ipsilateral side: 1.50 ± 0.33 ; contralateral side: 1.52 ± 0.24). The highest CBV was recorded in insula (ipsilateral side: 2.19 ± 0.71 ; contralateral side: 2.19 ± 0.64), cerebellum (ipsilateral side: 2.08 ± 0.68 ; contralateral side: 1.85 ± 0.68) and parietal cortex (ipsilateral side: 1.95 ± 0.49 ; contralateral side: 1.92 ± 0.32). All values were provided in millilitres of blood per 100 g of brain tissue (ml/100 g).

The highest CVR in response to the acetazolamide test was observed in temporal lobe cortex (ipsilateral side: $+27.1\%$; contralateral side: $+26.1\%$) and cerebellum (ipsilateral side: $+27.0\%$; contralateral side: $+34.6\%$). The lowest CVR was recorded in brainstem (ipsilateral side: $+20.2\%$; contralateral side: $+22.2\%$) and white matter (ipsilateral side: $+18.1\%$; contralateral side: $+18.3\%$).

The lowest resting state MTT was observed in the insula (ipsilateral side: 3.93 ± 1.80 ; contralateral side: 3.05 ± 0.57) and thalamus (ipsilateral side: 3.67 ± 0.80 ; contralateral side: 3.50 ± 0.64). However, MTT in the brainstem (ipsilateral side: 4.31 ± 1.162 ; contralateral side: 4.23 ± 1.31) and cerebellum (ipsilateral side: 4.31 ± 1.0 ; contralateral side: 4.21 ± 0.73) was also relatively low. The highest resting state MTT values were recorded in white matter (ipsilateral side: 5.42 ± 1.35 ; contralateral side: 4.73 ± 0.92) and occipital cortex (ipsilateral side: 5.58 ± 1.46 ; contralateral side: 5.35 ± 1.01). All MTT values were provided in seconds (s).

The MTT response to the acetazolamide test was relatively uniform. The highest decrease in MTT was observed in brainstem (ipsilateral side: -28.2% ; contralateral side: -25.6%) and cerebellum (ipsilateral side: -19.0% ; contralateral side: -22.2%).

The lowest resting state TTP was observed in the insula (ipsilateral side: 25.1 ± 4.5 ; contralateral side: 24.7 ± 4.3), the highest in white matter (ipsilateral side: 26.9 ± 3.5 ; contralateral side: 26.5 ± 4.09) and occipital cortex (ipsilateral side: 26.6 ± 3.8 ; contralateral side: 26.5 ± 4.2). Nevertheless, the resting TTP was relatively uniform across the

various brain structures. All TTP values were provided in seconds (s).

TTP responses to the acetazolamide test were similar across the various brain regions.

DISCUSSION

To the best of our knowledge, this is the first study describing regional cerebral perfusion pattern in subjects with chronic carotid artery stenosis. There are several new findings to report. Resting state CBF was low in frontal, parietal, temporal and particularly in occipital cortex grey matter in subjects with carotid artery stenosis. The CBF observed in insula and cerebellum was relatively high. The relatively uniform response to acetazolamide challenge seems to confirm well-developed collateral blood flow in subjects with chronic carotid artery stenosis. As expected grey matter was more reactive to acetazolamide challenge than white matter or brainstem.

Resting state

Our study demonstrates substantial spatial nonuniformity in all CTP parameters in the resting state, both cortically and subcortically, independent of the hemisphere (ipsi- or contra-lateral to stenosis). In this respect, our study is consistent with an earlier arterial-spin labeling (ASL) report in healthy subjects of various ages (Chen *et al.*, 2011). However, that examination was limited to cortical and subcortical regions, which is why we also assessed white matter, brainstem, and cerebellum.

Radiation exposure is unavoidable in CTP and represents one of the main disadvantages of this imaging technique. For this reason, the inclusion of a group of healthy control subjects is ethically impossible. Nevertheless, CTP has been shown to correlate well with positron emission tomography (PET) data, the gold standard for brain per-

fusion measurement (Kudo *et al.*, 2003). Also, other radiological neuroimaging techniques such as ASL (Kamano *et al.*, 2013; Zhang *et al.*, 2014) and single photon emission computed tomography (SPECT) (Matsumoto *et al.*, 2013) have been validated against PET. Therefore, some limited parallel comparisons can be made with caution.

The CBF in cortex grey matter (frontal, parietal and temporal) in our population was relatively low, particularly on the ipsilateral side. In Chen and coworkers (2011) ASL study in healthy subjects the mean CBF value across the entire cortical grey matter volume was 52.6 ± 9.3 , 52.0 ± 10.7 , and 42.7 ± 8.8 ml/100 g/min in the young (age < 40 years), middle-aged ($40 \leq \text{age} \leq 60$ years) and older adult groups (age ≥ 60 years), respectively. Similar results in healthy volunteers were obtained by Pantano and coworkers (1984) in PET study. The MTT in the frontal, parietal and temporal cortices grey matter was within the normal range (3–5 s), suggesting relatively balanced circulation and perfusion pressure (Schumann *et al.*, 1988; Murphy *et al.*, 2011). The moderate CBF decline in subjects with chronic carotid stenosis is in line with other reports by our team and others (Szarmach *et al.*, 2017a; Szarmach *et al.*, 2017b; Niesen *et al.*, 2004; Trojanowska *et al.*, 2006).

The very low CBF in the occipital cortex was quite striking. The CBF in the occipital cortex can be altered even in cognitively intact and nondemented subjects in the seventh decade of age (Trojanowska *et al.*, 2006). However, the hypometabolic occipital cortex is suggested to be prognostic for the development of mild cognitive impairment (Pikkarainen *et al.*, 2009). Ashraf and coworkers (2015) assessed glucose metabolism with PET. Although PET of tissue metabolic activity based on regional glucose uptake does not directly measure CBF, glucose metabolism and CBF are closely correlated and often show similar results (Baron *et al.*, 1982). Also, an MTT in occipital cortex grey matter above 5 s may indicate impaired circulation haemodynamics (Schumann *et al.*, 1988; Murphy *et al.*, 2011) in subjects with chronic carotid artery stenosis.

The role of the cerebellum in non-motor functions is increasingly recognized. Its involvement in cognitive functions is supported by the clinical finding that lesions confined to the cerebellum produce cerebellar cognitive affective syndrome (reviewed by Tedesco *et al.*, 2011). The cerebellum contains more than half of all the neurons in the brain, and exhibits strong interconnections with the contralateral cerebral hemisphere both in feedforward and feedback directions (Tedesco *et al.*, 2011). However, it remains to be elucidated how changes in cerebral cortex grey matter may affect the cerebellum. Due to the parallel characteristics of cerebello-cerebral connections (Van Overwalle *et al.*, 2017) it is tempting to speculate that the high cerebellar CBF observed in our study is compensatory in nature. In particular, the MTT in the cerebellar cortex remained low, indicating well-balanced circulation.

Changes in biochemical markers suggestive of underlying inflammation or glial activation have been demonstrated in the insula and thalamus in subjects with obstructive sleep apnoea, a disease characterized by intermittent episodes of nocturnal hypoxia. Importantly, the greatest biochemical alterations accompanied the lowest oxygen saturation (Yadav *et al.*, 2014; Sarma *et al.*, 2016). It is very likely that such alterations are also present in subjects with chronic carotid artery stenosis due to misery perfusion, prolonged hypoxia and oxidative stress (Szarmach *et al.*, 2017b). Therefore the high CBF present in our patient population might be due to inflammatory changes in these structures. Alternatively, both the insula and thalamus are involved in sympathetic brain responses triggered by oxidative stress and the activated renin-angiotensin-aldos-

terone system (Winklewski *et al.*, 2015; Winklewski *et al.*, 2016). Sympathetic activation may add functional component that further explains augmented CBF. The low MTT suggests well-balanced circulation in these structures.

The brainstem represents an evolutionarily old structure that is responsible for the maintenance and integration of vital homeostatic and life support functions (i.e., cardiovascular, respiratory, etc., Noble *et al.*, 1984). In the extreme conditions of complete anoxia in cats, the survival time of cerebral structures appeared to be related to the CBF, with older structures surviving 25–40 s and the cerebral cortex surviving only 14–15 s (Sugar & Gerard, 1938). Therefore, in our study, the preserved CBF in phylogenetically old brain regions such as the brainstem, cerebellum, thalamus, and insula may be explained by their high reactivity to persistent hypoxia that is likely present in the described subject population.

Delayed acetazolamide test

Delayed acetazolamide challenge led to a relatively uniform response on the ipsi- and contra-lateral sides to the stenosis. It is likely that all patients in the studied population had well-developed collateral flow as the duration of carotid artery stenosis exceeded 5 years (Barnett *et al.*, 1997; Waaijer *et al.*, 2007). The highest difference between stenotic and non-stenotic territories was visible in MTT response in cerebral cortex grey matter. A higher cortex MTT response on the contralateral side might be due to delayed reactivity on this side, and/or wearing off of the acetazolamide effect on the ipsilateral cortex (Murakami *et al.*, 2002; Hartkamp *et al.*, 2012).

As expected the highest CVR was recorded in cortex grey matter, while the lowest was in the white matter and brainstem. Significant differences in CO₂ reactivity between the internal carotid artery and vertebrobasilar circulation have been proposed in several physiological Doppler studies. According to physiologists lower CO₂ reactivity in the vertebrobasilar system may reflect conservative and relatively stable blood flow to the medulla oblongata to maintain vital systemic functions, while high CO₂ reactivity in the internal carotid artery system ensures proper tolerance to varied blood flow demand in the cerebral cortex (Sato *et al.*, 2012; Skow *et al.*, 2013). Our study confirms that structures fed by the vertebrobasilar system (brain stem, occipital cortex and cerebellum) have a relatively low CVR. Surprisingly, a relatively low CVR was also observed in the insula and thalamus. This suggests that the compensatory reserve of these structures has already been partially exhausted. Such a conclusion is supported by Ito and coworkers (2002), who reported that subcortical structures like the thalamus and putamen received relatively large increases in CBF during hypercapnia in healthy subjects.

Low CO₂ reactivity in white matter is typically explained by its relatively lower degree of vascularization compared to grey matter (Mandell *et al.*, 2008; Bhogal *et al.*, 2014). Mandell and coworkers (2008) demonstrated a CBF “stealing effect” in white matter in response to rapid CO₂ partial tension increases. Interestingly, a selective reduction in CBF to white matter during mild hypercapnia in young, healthy human subjects occurs precisely in those locations where elderly patients develop leukoaraiosis (Mandell *et al.*, 2008). Our results collected one hour after acetazolamide challenge support the concept that white matter CVR is low compared to other structures. Consequently, its ability to respond to variations in CO₂ supply might be deteriorated in older subjects.

Delayed acetazolamide test might be better suited for elderly subjects with several cardiovascular diseases and



most likely diminished CVR. To the best of our knowledge our team is the first to show that the acetazolamide effect persists for at least 60 minutes in subjects with chronic carotid artery stenosis (Szarmach *et al.*, 2017a). There is accumulating evidence that CVR should be seen as a process of temporally and spatially defined dynamics rather than a single value based on measurement at the point of the highest response (Bhogal *et al.*, 2014; Bhogal *et al.*, 2015; Bhogal *et al.*, 2016). It has been demonstrated that various white (WM) and grey matter (GM) structures in healthy subjects show substantial differences in CVR to increasing concentrations of breathing carbon dioxide (CO₂, Bhogal *et al.*, 2014). This pattern of CVR complexity in time and space is further complicated by changes observed in healthy aging (Bhogal *et al.*, 2015; Bhogal *et al.*, 2016; Nöth *et al.*, 2008). Future studies in subjects with chronic carotid artery stenosis may also benefit from dynamic CVR assessment.

Computed tomography imaging and especially computed tomography perfusion (CTP) is still more commonly used than magnetic resonance imaging (MRI) because CTP has many advantages over MRI. CTP has better spatial resolution than MRI perfusion with significantly shorter study time. In this project acquisition time was less than one minute. Campbell *et al.* (2012) reported that quantitative computer tomography perfusion mismatch classification using two main parameters is similar to a diffusion-perfusion mismatch in MRI. Imaging by MRI is very tempting because it does not use ionizing radiation. But magnetic resonance imaging has many contraindications (e.g., pacemakers, neurostimulators, cochlear implants, and claustrophobia), the study takes a long time, and patients have to remain still while scanning. Also, emergency departments are often not equipped with an MRI scanner. These key arguments favour the use of CTP.

Quantitative CTP data is highly dependent on the post-processing software and the investigators. Software differences are frequently considered the main cause of variability in perfusion results relative to interoperator and intraoperator differences (Kudo *et al.*, 2010; Kamalian *et al.*, 2011). To avoid technical mistakes we used equipment manufactured by one producer and used the same post-processing procedure for all subjects, increasing the reliability of the study. Furthermore, both experienced neuroradiologists independently drew two standardized elliptical mirrored ROIs in the same patients twice (before and after acetazolamide administration; Fig 1 and 2, SF1). Finally, in all subjects, we used a coverage size of 40 mm, which is well suited for detecting perfusion parameters owing to the high density of the scans (Szarmach *et al.*, 2016).

The number of studied subjects involved in the study is relatively small and heterogeneous in terms of medical history, including previous history of stroke, carotid artery endarterectomy and stenting. The study population is nevertheless representative for a group of patients with chronic carotid artery stenosis (Szarmach *et al.*, 2016; Szarmach *et al.*, 2017a; Szarmach *et al.*, 2017b). Moreover, the study group is very homogeneous with respect to low CBV and CBF values due to strict inclusion criteria (carotid stenosis >90% on the ipsilateral side, less than 50% on the contralateral side, complete circle of Willis and normal vertebral arteries).

The study raises several important questions from the clinical perspective that should be answered in future research. Is the low resting state CBF in occipital grey cortex related to cognitive impairment in the studied population? Is the high resting state CBF in the cerebellum compensatory in nature? Are the observed results in the insula and thalamus compensatory or inflammato-

ry in nature? Finally, how do the described changes affect functional outcome and prognosis? Future research may include combined ASL, BOLD-MRI, and dynamic contrast-enhanced (DCE)-MRI studies to address these questions. Hypoxia and inflammation are increasingly recognized as the pathophysiological background in several neurological and psychiatric diseases. Consequently, in-depth studies in larger groups of subjects suffering from prolonged hypoxia and the chronic inflammatory state may provide benefits to several fields in medicine.

CONCLUSIONS

To conclude, we have shown a relatively low resting state CBF in frontal, parietal and temporal cortex grey matter in subjects with carotid artery stenosis. A particularly low CBF was evident in the occipital cortex. The MTT in cortex grey matter tentatively suggests a balanced circulation. The high resting state CBF observed in the insula and cerebellum might be compensatory or inflammatory in nature. The relatively uniform response to acetazolamide challenge seems to confirm well-developed collateral blood flow in subjects with chronic carotid artery stenosis. Grey matter is more reactive to acetazolamide challenge than white matter or brainstem in the studied population.

Author contributions

AS and PJW conceived and designed the experiments; AS, GH and MP performed the experiments; AS, MK and PJW analysed the data; AS, GH, MK, AF, MP, JD, MS, PL, ES, PJW wrote or critically reviewed the manuscript; all authors accepted the final version of the manuscript.

Conflict of interest

None.

REFERENCES

- Abbott A (2016) Critical issues that need to be addressed to improve outcomes for patients with carotid stenosis. *Angiology* **67**: 420–426. Doi: 10.1177/00033197166631266
- Ashraf A, Fan Z, Brooks DJ, Edison P (2015) Cortical hypermetabolism in MCI subjects: a compensatory mechanism? *Eur J Nucl Med Mol Imaging* **42**: 447–458. Doi: 10.1007/s00259-014-2919-z
- Barnett HJ (1997) Hemodynamic cerebral ischemia. An appeal for systematic data gathering prior to a new EC/IC trial. *Stroke* **28**: 1857–1860
- Baron JC, Lebrun-Grandie P, Collard P, Crouzel C, Mestelan G, Bousser MG (1982) Noninvasive measurement of blood flow, oxygen consumption, and glucose utilization in the same brain regions in man by positron emission tomography: concise communication. *J Nucl Med* **23**: 391–399
- Bhogal AA, Siero JC, Fisher JA, Froeling M, Luijten P, Philippens M, Hoogduin H (2014) Investigating the non-linearity of the BOLD cerebrovascular reactivity response to targeted hypo/hypercapnia at 7T. *Neuroimage* **98**: 296–305. Doi: 10.1016/j.neuroimage.2014.05.006
- Bhogal AA, Philippens ME, Siero JC, Fisher JA, Petersen ET, Luijten PR, Hoogduin H (2015) Examining the regional and cerebral depth-dependent BOLD cerebrovascular reactivity response at 7T. *Neuroimage* **114**: 239–248. Doi: 10.1016/j.neuroimage.2015.04.014
- Bhogal AA, De Vis JB, Siero JC, Petersen ET, Luijten PR, Hendrikse J, Philippens ME, Hoogduin H (2016) The BOLD cerebrovascular reactivity response to progressive hypercapnia in young and elderly. *Neuroimage* **139**: 94–102. Doi: 10.1016/j.neuroimage.2016.06.010
- Campbell BC, Christensen S, Levi CR, Desmond PM, Donnan GA, Davis SM, Parsons MW (2012) Comparison of computed tomography perfusion and magnetic resonance imaging perfusion-diffusion mismatch in ischemic stroke. *Stroke* **43**: 2648–2653
- Chen JJ, Rosas HD, Salat DH (2011) Age-associated reductions in cerebral blood flow are independent from regional atrophy. *Neuroimage* **55**: 468–478. Doi: 10.1016/j.neuroimage.2010.12.032
- Frydrychowski AF, Winklewski PJ, Szarmach A, Halena G, Bandurski T (2013) Near-infrared transillumination back scattering sounding –



- new method to assess brain microcirculation in patients with chronic carotid artery stenosis. *PLoS One* **8**: e61936. Doi: 10.1371/journal.pone.0061936
- Hartkamp NS, Hendrikse J, van der Worp HB, de Borst GJ, Bokers RP (2012) Time course of vascular reactivity using repeated phase-contrast MR angiography in patients with carotid artery stenosis. *Stroke* **43**: 553–556. Doi: 10.1161/STROKEAHA.111.637314
- Hokari M, Kuroda S, Shiga T, Nakayama N, Tamaki N, Iwasaki Y (2008) Combination of a mean transit time measurement with an acetazolamide test increases predictive power to identify elevated oxygen extraction fraction in occlusive carotid artery diseases. *J Nucl Med* **49**: 1922–1927. Doi: 10.2967/jnumed.108.054379
- Ito H, Kanno I, Ibaraki M, Hatazawa J (2002) Effect of aging on cerebral vascular response to PaCO₂ changes in humans as measured by positron emission tomography. *J Cereb Blood Flow Metab* **22**: 997–1003
- Kamalian S, Kamalian S, Maas MB, Goldmacher GV, Payabvash S, Akbar A, Schaefer PW, Furie KL, Gonzalez RG, Lev MH (2011) CT cerebral blood flow maps optimally correlate with admission diffusion-weighted imaging in acute stroke but thresholds vary by postprocessing platform. *Stroke* **42**: 1923–1928. Doi: 10.1161/STROKEAHA.110.610618
- Kamano H, Yoshiura T, Hiwatashi A, Abe K, Togao O, Yamashita K, Honda H (2013) Arterial spin labeling in patients with chronic cerebral artery steno-occlusive disease: correlation with (15)O-PET. *Acta Radiol* **54**: 99–106. Doi: 10.1258/ar.2012.120450
- Kudo K, Sasaki M, Yamada K, Momoshima S, Utsunomiya H, Shirato H, Ogasawara K (2010) Differences in CT perfusion maps generated by different commercial software: quantitative analysis by using identical source data of acute stroke patients. *Radiology* **254**: 200–209. Doi: 10.1148/radiol.254082000
- Kudo K, Terae S, Katoh C, Oka M, Shiga T, Tamaki N, Miyasaka K (2013) Quantitative cerebral blood flow measurement with dynamic perfusion CT using the vascular-pixel elimination method: comparison with H2(15)O positron emission tomography. *AJNR Am J Neuroradiol* **24**: 419–426
- Murphy MJ, Tichauer KM, Sun L, Chen X, Lee TY (2011) Mean transit time as an index of cerebral perfusion pressure in experimental systemic hypotension. *Physiol Meas* **32**: 395–405. Doi: 10.1088/0967-3334/32/4/002
- Mandell DM, Han JS, Poubanc J, Crawley AP, Kassner A, Fisher JA, Mikulis DJ (2008) Selective reduction of blood flow to white matter during hypercapnia corresponds with leukoaraiosis. *Stroke* **39**: 1993–1998. Doi: 10.1161/STROKEAHA.107.501692
- Matsumoto Y, Ogasawara K, Saito H, Terasaki K, Takahashi Y, Ogasawara Y, Kobayashi M, Yoshida K, Beppu T, Kubo Y, Fujiwara S, Tsushima E, Ogawa A (2013) Detection of misery perfusion in the cerebral hemisphere with chronic unilateral major cerebral artery steno-occlusive disease using crossed cerebellar hypoperfusion: comparison of brain SPECT and PET imaging. *Eur J Nucl Med Mol Imaging* **40**: 1573–1581. Doi: 10.1007/s00259-013-2463-2
- MRC European Carotid Surgery Trial (1991) interim results for symptomatic patients with severe (70–99%) or with mild (0–29%) carotid stenosis. European Carotid Surgery Trialists' Collaborative Group. *Lancet* **337**: 1235
- Murakami M, Yonehara T, Takaki A, Fujioka S, Hirano T, Ushio Y (2002) Evaluation of delayed appearance of acetazolamide effect in patients with chronic cerebrovascular ischemic disease: feasibility and usefulness of SPECT method using triple injection of ECD. *J Nucl Med* **43**: 577–583
- Niesen WD, Rosenkranz M, Eckert B, Meissner M, Weiller C, Sliwka U (2004) Hemodynamic changes of the cerebral circulation after stent-protected carotid angioplasty. *AJNR Am J Neuroradiol* **25**: 1162–1167
- Noble J, Jones JG, Davis EJ (1984) Cognitive function during moderate hypoxaemia. *Anaesth Intensive Care* **21**: 180–184
- North American Symptomatic Carotid Endarterectomy Trial (NASCET) Collaborators (1991) Beneficial effect of carotid endarterectomy in symptomatic patients with high-grade carotid stenosis. *New Engl J Med* **325**: 445–453
- Nöth U, Kotajima F, Deichmann R, Turner R, Corfield DR (2008) Mapping of the cerebral vascular response to hypoxia and hypercapnia using quantitative perfusion MRI at 3 T. *NMR Biomed* **21**: 464–472
- Pantano P, Baron JC, Lebrun-Grandié P, Duquesnoy N, Bousser MG, Comar D (1984) Regional cerebral blood flow and oxygen consumption in human aging. *Stroke* **15**: 635–641
- Pikkarainen M, Kauppinen T, Alafuzoff I (2009) Hyperphosphorylated tau in the occipital cortex in aged nondemented subjects. *J Neuro-pathol Exp Neurol* **68**: 65–60. Doi: 10.1097/NEN.0b013e3181a6ee45
- Sarma MK, Macey PM, Nagarajan R, Aysola R, Harper RM, Thomas MA (2016) Accelerated echo planar J-resolved spectroscopic imaging of putamen and thalamus in obstructive sleep Apnea. *Sci Rep* **6**: 31747. Doi: 10.1038/srep31747
- Sato K, Sadamoto T, Hirasawa A, Oue A, Subudhi AW, Miyazawa T, Ogoh S (2012) Differential blood flow responses to CO₂ in human internal and external carotid and vertebral arteries. *J Physiol* **590**: 3277–3290. Doi: 10.1113/jphysiol.2012.230425
- Schumann P, Touzani O, Young AR, Morello R, Baron JC, MacKenzie ET (1998) Evaluation of the ratio of cerebral blood flow to cerebral blood volume as an index of local cerebral perfusion pressure. *Brain* **121**: 1369–1379. Erratum in: *Brain* **121**: 2027
- Skow RJ, MacKay CM, Tymko MM, Willie CK, Smith KJ, Ainslie PN, Day TA (2013) Differential cerebrovascular CO₂ reactivity in anterior and posterior cerebral circulations. *Respir Physiol Neurobiol* **189**: 76–86. Doi: 10.1016/j.resp.2013.05.036
- Szarmach A, Halena G, Kaszubowski M, Piskunowicz M, Szurowska E, Frydrychowski AF, Winklewski PJ (2016) Perfusion computed tomography: 4 cm versus 8 cm coverage size in subjects with chronic carotid artery stenosis. *Br J Radiol* **89**: 20150949. Doi: 10.1259/bjr.20150949
- Szarmach A, Winklewski PJ, Halena G, Kaszubowski M, Dzierżanowski J, Piskunowicz M, Szurowska E, Frydrychowski AF (2017a) Morphometric evaluation of the delayed cerebral arteries response to acetazolamide test in patients with chronic carotid artery stenosis using computed tomography angiography. *Folia Morphol* **76**: 10–14. Doi: 10.5603/FMa.2016.0034
- Szarmach A, Halena G, Kaszubowski M, Piskunowicz M, Studniarek M, Lass P, Szurowska E, Winklewski PJ (2017b) Carotid artery stenting and blood–brain barrier permeability in subjects with chronic carotid artery stenosis. *Int J Mol Sci* **18**: 1008. Doi: 10.3390/ijms18051008
- Sugar O, Gerard RW (1938) Anoxia and brain potentials. *J Neurophysiol* **1**: 558–572
- Tedesco AM, Chiricozzi FR, Clausi S, Lupo M, Molinari M, Leggio MG (2011) The cerebellar cognitive profile. *Brain* **134**: 3672–3686. Doi: 10.1093/brain/awr266
- Trojanowska A, Drop A, Jargiello T, Wojczal J, Szerber-Trojanowska M (2006) Changes in cerebral hemodynamics after carotid stenting: evaluation with CT perfusion studies. *J Neuroradiol* **33**: 169–174
- Yadav SK, Kumar R, Macey PM, Woo MA, Yan-Go FL, Harper RM (2014) Insular cortex metabolite changes in obstructive sleep apnea. *Sleep* **37**: 951–958. Doi: 10.5665/sleep.3668
- Van Overwalle F, Heleven E, Ma N, Mariën P (2017) Tell me twice: A multi-study analysis of the functional connectivity between the cerebrum and cerebellum after repeated trait information. *Neuroimage* **144**: 241–252. Doi: 10.1016/j.neuroimage.2016.08.046
- Vorstrup S, Henriksen L, Paulson OB (1984) Effect of acetazolamide on cerebral blood flow and cerebral metabolic rate for oxygen. *J Clin Invest* **74**: 1634–1639
- Vorstrup S, Brun B, Lassen NA (1986) Evaluation of the cerebral vasodilatory capacity by the acetazolamide test before EC-IC bypass surgery in patients with occlusion of the internal carotid artery. *Stroke* **17**: 1291–1298
- Wardlaw JM, Allerhand M, Eadie E, Thomas A, Corley J, Pattie A, Taylor A, Shenkin SD, Cox S, Gow A, Starr JM, Deary IJ (2017) Carotid disease at age 73 and cognitive change from age 70 to 76 years: A longitudinal cohort study. *J Cereb Blood Flow Metab* **37**: 3042–3052. Doi: 10.1177/0271678X16683693
- Waaiaer A, van Leeuwen MS, van Osch MJ, van der Worp BH, Moll FL, Lo RT, Mali WP, Prokop M (2007) Changes in cerebral perfusion after revascularization of symptomatic carotid artery stenosis: CT measurement. *Radiology* **245**: 541–548
- Winklewski PJ, Radkowski M, Wszedybyl-Winklewska M, Demkow U (2015) Brain inflammation and hypertension: the chicken or the egg? *J Neuroinflammation* **12**: 85. Doi: 10.1186/s12974-015-0306-8
- Winklewski PJ, Radkowski M, Demkow U (2016) Neuroinflammatory mechanisms of hypertension: potential therapeutic implications. *Curr Opin Nephrol Hypertens* **25**: 410–416. Doi: 10.1097/MNH.0000000000000250
- Wintermark M, Reichhart M, Thiran JP, Maeder P, Chalaron M, Schnyder P, Bogousslavsky J, Meuli R (2002) Prognostic accuracy of cerebral blood flow measurement by perfusion computed tomography, at the time of emergency room admission, in acute stroke patients. *Ann Neurol* **51**: 417–432
- Zhang K, Herzog H, Mauler J, Filss C, Okell TW, Kops ER, Tellmann L, Fischer T, Brocke B, Sturm W, Coenen HH, Shah NJ (2014) Comparison of cerebral blood flow acquired by simultaneous [15O] water positron emission tomography and arterial spin labeling magnetic resonance imaging. *J Cereb Blood Flow Metab* **34**: 1373–1380. doi: 10.1038/jcbfm.2014.92.