



Indexed Journal

Website: [www.ijomcr.net](http://www.ijomcr.net)Email : [ijomcr@gmail.com](mailto:ijomcr@gmail.com)

ISSN- 2455-0574

**International Journal Of Medical Case Reports****HALOPERIDOL-INDUCED TORSADES DE POINTES: A CASE REPORT.**

Authors

Dr.Javed Ather Siddiqui<sup>1</sup>,Dr.Shazia Farheen Qureshi<sup>2</sup>,Dr.Ali Mahmoud Eldaous<sup>3</sup>,Dr.Waseem, M Marei<sup>4</sup>.<sup>1,2,3</sup>Psychiatrist, <sup>4</sup>Consultant psychiatrist, Mental Hospital Taif (KSA)

Corresponding Author

**Dr.Javed Ather Siddiqui****ABSTRACT**

Torsades de pointes (Tdp) is a malignant polymorphic ventricular arrhythmia<sup>1</sup> often associated with drugs like haloperidol that prolonged QTc interval<sup>2</sup>. If enough care is not taken this may lead to sudden death. This can occur at normal therapeutic doses with either oral<sup>3,4</sup> or intravenous use<sup>5</sup>.

We report here a case of 35 years old female who was a known case of schizophrenia. She was admitted in our hospital for aggressive behavior. She was on haloperidol. On ECG there was evidence of prolonged QT interval. During her stay in hospital she developed potentially life threatening arrhythmia torsades de pointes.

**Key Words:** Haloperidol, Torsades de pointes, Malignant Polymorphic ventricular arrhythmia.

## INTRODUCTION

Haloperidol is a butyrophenone derivative, typical antipsychotics drug still used in the treatment of psychotic disorder, agitation and aggressive behavior, delirium and mania. It acts on D2 blockage and inhibits alfa 1 adrenergic receptor<sup>6</sup>. It has less effect on muscarinic, cholinergic or histaminergic receptors. The use of this medication may lead to severe complications including hypotension, prolomged QT interval and in severe cases sudden death<sup>7</sup>. We aimed to report a case of malignant polymorphic ventricular arrhythmia (Tdp) occurring with the use of haloperidol in this study<sup>8</sup>. The QT interval is an electrocardiographic measure of both depolarization and repolarization within heart. It is measured as the distance between the beginning of QRS complex and the end of T wave. The QTc is used to assess the conduction status within the heart. The QTc in healthy person is 440 m sec for men and 470 m sec for women. If QTc is more than 500m sec then it is considered prolonged and associated with an increased risk of arrhythmias, including Tdp. Tdp is a malignant polymorphic ventricular arrhythmia which lengthen the QTc . Polymorphic ventricular arrhythmias may be precipitated by many drugs including Psychotropics like

haloperidol, pimozide, ziprasidone, thioridazine and many others. Non-psychotropics drugs causing Polymorphic ventricular arrhythmias includes antibiotics like erythromycin and clarithromycine, antimalarials like chloroquine and quinine, antiarrhythmics like quinidine and procainamide and many more.

Action to be taken if QTc is found to be over 500 m sec includes stoppage of suspected causative drugs and switch to drug of lowest effect and refer to cardiologist immediately.

## CASE REPORT:

A 35 years old female patient known case of schizophrenia was admitted to our hospital for her aggressive behavior. She has no history of any organic disease and of any cardiac risk factor. The patient was diagnose case of schizophrenia. She was taking oral haloperidol 20mg per day with oral benztropine 4mg per day along with intramuscular haloperidol 5mg 8 hourly to control her agitation, disorganized behavior, auditory hallucination and paranoid delusion. At the day 4 of her admission, she developed sudden shortness of breath and syncopal attack.

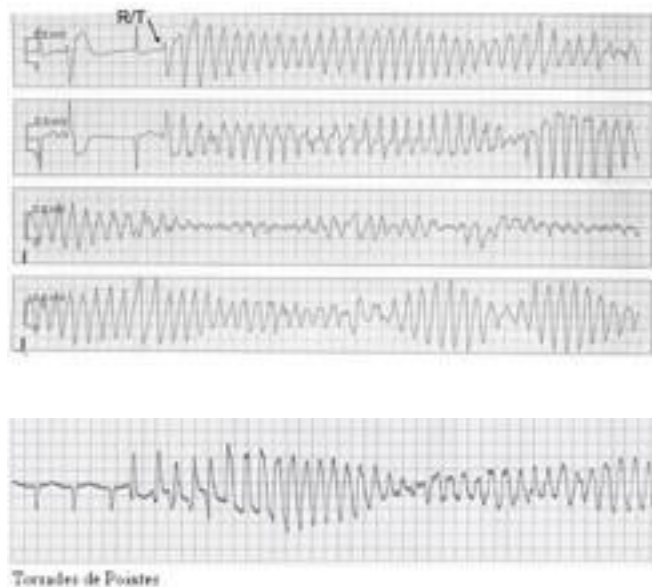


Fig 1: Torsades de pontes following haloperidol therapy.

On physical examination vitals were within normal limits, investigations of serum electrolytes and myocardial enzyme level were normal. The patient who was monitoring during clinical care experienced ECG changes, shows normal sinus rhythm, and prolong QTc 650 msec, continuous ECG monitoring revealed frequent ventricular premature contraction with varying coupling interval as well as spontaneous bursts of fast ventricular tachycardia at a rate 220 per min. The pattern was compatible with the polymorphous configuration of torsades de pointes. We shifted patient to cardiac care unit there Isoproterenol infusion at a rate of 2-3 mg/min was started and titrated to achieve a heart rate of

110-115 beats per min, ventricular premature contractions disappeared at heart rate 100/min, 24 hours later QT interval became normal and isoproterenol infusion was discontinued, no arrhythmia was observed during next 24 hours and QT interval shortened to 380msec.

#### DISCUSSION:

Toxic doses of haloperidol and many other drugs may precipitate torsades de pointes, Ventricular premature contractions after rapid "neuroleptization" have been reported<sup>9</sup> as well as unexpected sudden death during therapy with haloperidol.

Overdrive pacing and isoproterenol<sup>10</sup> have been successfully used in the suppression of torsades de pointes. Other antipsychotics drugs are known to cause a dose dependent prolongation of the QT interval and develop Tdp, but most reported cases were due to thioridazine and other were related to phenothiazines and still others due to tricyclic antidepressants and other medications.

#### CONCLUSION:

Our case report and other literature suggest that oral normal therapeutic doses, intravenous use and toxic over doses of

haloperidol prolong QTc interval and precipitating arrhythmia torsades de pointes.

Clinicians should be aware of haloperidol's potential to induce torsades de pointes, since it is used regularly for agitation.

## REFERENCES:

- 1) Myerburg RJ, Castellanos A, Kessler KM. Clinical assessment and management of arrhythmias and conduction disturbances. New York: McGraw Hill Inc 1994; 745.
- 2) Zee cheng CHS, Mueller CE, Seifer CHF, Gibbs HR. Haloperidol and torsade de pointes. *Ann Intern Med* 1985; 102:18
- 3) Fayer SA: Torsades de pointes ventricular tachyarrhythmia associated with haloperidol. *J Clin Psychopharmacol* 1986;
- 4) Kriwisky M, Perry GY, Tarchitsky D, Gutman Y, Kishon Y: Haloperidol induced torsades de pointes, *Chest* 1990; 98:482-484.
- 5) Hunt N, Stem TA: The association between intravenous haloperidol and torsades de pointes. *Psychosomatics* 1995;36: 541-549.
- 6) Uzbay T, Stahl in Temel Psikofarmakolojiski Istanbul: Istanbul Medical Yayncilik, 2012
- 7) Ravin DS, Levenson JW. Fatal cardiac event following initiation of risperidone therapy. *Ann Pharmacother.* 1997;31:867-70
- 8) Fayer SA, Torsades de pointes ventricular tachyarrhythmia associated with haloperidol. *J Clin Psychopharmacol* 1986; 6:375-6
- 9) Lever P, sudden death is a risk of neuroleptic treatment . *Psychopharmacol Bull* 1981; 17;6-9.
- 10) Gallanger JJ, Smith WM, Les torsades de pointes. *Ann Intern Med* 1980;93:578-84