





## REVIEW ARTICLE

# Lessons learned in a decade: Medical-toxicological view of tattooing

Michael Giulbudagian<sup>1</sup>  | Beatrice Battisini<sup>2</sup> | Wolfgang Bäuml<sup>3</sup> | Ana M. Blass Rico<sup>4</sup> | Beatrice Bocca<sup>2</sup> | Corinna Brungs<sup>5</sup> | Marco Famele<sup>6</sup> | Milena Foerster<sup>7</sup> | Birgit Gutsche<sup>8</sup> | Veit Houben<sup>9</sup> | Urs Hauri<sup>10</sup> | Katarzyna Karpienko<sup>11</sup> | Uwe Karst<sup>5</sup> | Linda M. Katz<sup>12</sup> | Nicolas Kluger<sup>13,14,15</sup>  | Jørgen Serup<sup>16</sup> | Ines Schreiber<sup>1</sup>  | Steffen Schubert<sup>17</sup>  | Sebastiaan A. S. van der Bent<sup>18</sup> | Carina Wolf<sup>5</sup> | Andreas Luch<sup>1</sup> | Peter Laux<sup>1</sup>

## Correspondence

Michael Giulbudagian, Department of Chemical and Product Safety, German Federal Institute for Risk Assessment (BfR), Max-Dohrn-Str. 8-10, 10589 Berlin, Germany.  
Email: michael.giulbudagian@bfr.bund.de

## Abstract

Tattooing has been part of the human culture for thousands of years, yet only in the past decades has it entered the mainstream of the society. With the rise in popularity, tattoos also gained attention among researchers, with the aim to better understand the health risks posed by their application. ‘A medical-toxicological view of tattooing’—a work published in *The Lancet* almost a decade ago, resulted from the international collaboration of various experts in the field. Since then, much understanding has been achieved regarding adverse effects, treatment of complications, as well as their regulation for improving public health. Yet major knowledge gaps remain. This review article results from the Second International Conference on Tattoo Safety hosted by the German Federal Institute for Risk Assessment (BfR) and provides a glimpse from the medical-toxicological perspective, regulatory strategies and advances in the analysis of tattoo inks.

## INTRODUCTION

Tattoo inks are mixtures of chemicals that are injected into the human skin. The medical-toxicological assessment of such multi-component mixtures requires an interdisciplinary understanding. This comprises technical aspects of tattoo ink production through their interaction with a viable tissue.<sup>1</sup> The production of tattoo inks requires pigments of different hues, solvents, emulsifiers, binders, thixotropic, antifoam agents and preservatives. The colouring pigments are either of inorganic or organic nature. Black and white are typically created by carbon black and titanium dioxide, respectively, and iron oxides may be used as black, red, and

yellow pigments. Most of the coloured tattoos are based on organic azo, quinacridone or Cu-phthalocyanine pigments.<sup>2,3</sup> These pigments show a high light absorption in narrow spectral ranges and, therefore, exhibit a high colour strength.

Using mm-size solid needles, tattoo inks are injected into skin, creating multiple small holes. That injury prompts the skin to perform different actions, which may be subdivided into three phases over different time spans: inflammation (up to 10 days), tissue formation (up to 3 months) and tissue remodelling (up to 1 year).<sup>4</sup> The inflammation phase includes haemostasis as well as the recruitment of neutrophils and macrophages. In the tissue formation phase, the initial

For affiliations refer to page 9.

This is an open access article under the terms of the [Creative Commons Attribution-NonCommercial-NoDerivs](https://creativecommons.org/licenses/by-nc-nd/4.0/) License, which permits use and distribution in any medium, provided the original work is properly cited, the use is non-commercial and no modifications or adaptations are made.

© 2024 The Authors. *Journal of the European Academy of Dermatology and Venereology* published by John Wiley & Sons Ltd on behalf of European Academy of Dermatology and Venereology.

action is the re-epithelialization of the epidermis, followed by the repair of blood vessels, nerves and eccrine sweat glands.<sup>4</sup> Complete remodelling of the injured skin may take up to 1 year. In the case of clean wounds, re-epithelialization of skin is usually completed within 1 week.<sup>5</sup> It is unexplored so far, whether wound healing and particularly skin re-epithelialization are altered by the chemical ingredients of the tattoo ink.

Histology has revealed that tattoo pigments move from the initial puncture location to randomly distributed locations in the dermis.<sup>6</sup> The pigment particles in skin are mainly located in the cytoplasm of different cells like fibroblasts and macrophages, which ensure the macroscopic stability and hence, the long-term persistence of tattoos in skin through a constant capture–release–recapture process.<sup>7,8</sup>

Directly after tattooing, a concentration range of 0.60–9.42 mg pigment per cm<sup>2</sup> of tattooed skin has been determined in excised pig and human skin.<sup>6</sup> However, this concentration is rapidly reduced by exudation processes that transport a part of tattoo colourants through the skin punctures to the outside. The concentration of the tattoo ink initially placed in skin additionally decreases after tattooing by the action of the immune system. Systemic transportation may occur actively with dendritic cells or passively with lymphatic fluid or blood. Neutrophilic granulocytes, macrophages or dendritic cells take up such material on site or transport it away through the lymphatic system.<sup>9,10</sup> Thus, tattoo inks, in particular the pigments, can be expected in all organs and indeed, were reported in the lymph nodes located next to the tattoo.<sup>11–17</sup> Specifically, the accumulation of particles in Kupffer cells of mice liver was suggested by observation with transmission electron microscopy (TEM) images taken after tattooing with black and red inks.<sup>18</sup> Nevertheless, the extent and the relevance of pigment transportation to other organs of the human body is still unknown, so are, consequently, possible related health risks.

After healing, pigment particles in the skin may be exposed to light, in particular ultraviolet (UV) radiation.<sup>19</sup> Hereby, pigment molecules may decompose upon UV, visible or infrared (IR) light from sunlight, lasers or other sources to yield new, possibly hazardous products.<sup>20,21</sup> The high intensities of laser radiation applied to tattoo removal may also cause various decomposition products.<sup>22–24</sup> Scientific data to

estimate the long-term health effects of radiation to tattooed skin and potentially other organs are scarce.

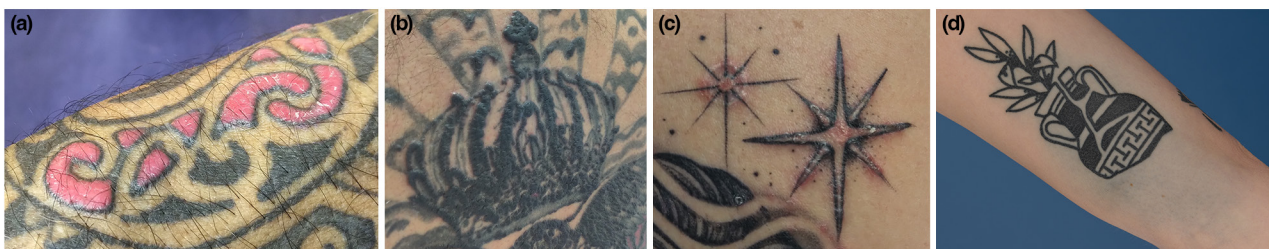
This review article presents the latest knowledge on medical complications of tattoos and permanent make-up (PMU) and their treatment strategies. Moreover, measures undertaken to protect consumers are discussed. Finally, advances in the analytics of tattoo inks and tattoo pigments are presented.

## HEALTH RISKS OF TATTOOS: CLINICAL EVIDENCE

### Categorization of tattoo complications and their treatment

Complications from tattoos and PMU can be categorized into inflammatory, infectious, proliferative and miscellaneous reactions (Figure 1; Table 1).<sup>25–28</sup> Of all tattoo complications, inflammatory allergic tattoo reactions are frequent. These reactions are characterized by chronic itch or pain, usually restricted to one tattoo colour. Although different colours except black (carbon black) may have allergic manifestations, reddish tattoo pigments are involved in the vast majority of cases estimated to be 97%.<sup>25,28</sup> The clinical variations include ‘plaque-type’ elevation, excessive hyperkeratosis or rarely ulceration.<sup>25,28</sup> The average time of onset of symptoms is 1 year after the tattoo is placed, varying from 1 month up to several years.<sup>29</sup> The histopathology is characterized by the combination of dermal predominantly histiocytic infiltrates and epidermal interface dermatitis.<sup>30,31</sup> Etiologically, these reactions are thought to be a delayed type IV allergy to tattoo pigments or their breakdown products.<sup>32,33</sup> Two recent studies suggested that 2-hydroxy-3-naphthanilide (naphthol AS) azo pigments are likely to be involved.<sup>34,35</sup>

Treatment modalities include topical or intralesional corticosteroids. However, for a permanent treatment result, removal of the culprit tattoo pigment is required. Full surface and fractional ablative CO<sub>2</sub> laser therapy, surgical excision or dermatome shaving are possible treatments.<sup>36,37</sup> As these therapies may lead to undesirable scars, especially in PMU, alternative therapy with systemic medication, including hydroxychloroquine, allopurinol and methotrexate in combination with Q-switched Nd:YAG (532 nm) laser therapy have



**FIGURE 1** Representative manifestations of tattooed skin complications. (a) Plaque-like allergic reaction to a red tattoo on the right lower arm, (b) chronic inflammatory black tattoo reaction with papulo-nodules on the upper back, (c) psoriasis vulgaris in a recent black tattoo on the right shoulder, (d) blow out around a black tattoo of the upper arm.

**TABLE 1** Clinical diagnosis of tattoo-associated complications by category.<sup>26,27</sup>

Category	Description of variation
Allergic reactions, local in the tattoo, 'plaque elevation' and other local reactions	<ul style="list-style-type: none"> <li>'Plaque elevation', flat elevation of one specific colour and in any tattoo with that particular colour injected, type IV allergy</li> <li>'Excessive hyperkeratosis', type IV allergy</li> <li>'Ulceronecrotic reaction', severe type IV allergy</li> <li>'Acneiform reaction', possibly with epidermoid inclusions</li> <li>Allergic reactions showing 'cross sensitivity reactions' with activation of older tattoos similar in colour</li> </ul>
Allergic reaction, general	<ul style="list-style-type: none"> <li>Dermatitis/rash, primary sensitization or by challenge (nickel, preservative etc.), type IV allergy</li> <li>Urticaria, widespread, type I allergy</li> <li>Anaphylaxis on laser removal, type I allergy</li> </ul>
'Papulo-nodular reaction', local and general, sarcoidosis associated	<ul style="list-style-type: none"> <li>Non-allergic inflammatory reaction, limited to parts of the tattoo that are more densely tattooed; with pigment agglomerates, sarcoid granuloma, or cutaneous sarcoidosis, associated with pulmonary, ocular or other systemic affection including erythema nodosum</li> <li>Older tattoos may react abruptly due to autoimmunity, the 'rush phenomenon'</li> <li>Known sarcoidosis of internal organ(s) secondarily afflicting the tattoo</li> </ul>
Bacterial infections	<ul style="list-style-type: none"> <li>Local, regional and possibly systemic with sepsis; Gram-positive human pathogens and environmental Mycobacteria</li> </ul>
Viral and other infections/infestations	<ul style="list-style-type: none"> <li>Papilloma and Herpes Simplex viruses</li> <li>Hepatitis B, C and HIV</li> <li>Lepra, syphilis, leishmaniasis</li> </ul>
Reactions induced by external factors including light ('photosensitivity')	<ul style="list-style-type: none"> <li>Light and sun induced urticaria-like tattoo reactions, mostly in dark tattoos, possibly Reactive Oxygen Species (ROS) mediated</li> <li>Urticaria-like reactions by heat, trauma, alcohol intake, affecting any tattoo</li> </ul>
'Neuro-sensitivity reaction'	<ul style="list-style-type: none"> <li>Chronic pain and hypersensitivity in tattoo, including chronic pain syndrome induced by tattooing</li> </ul>
Lymphadenopathy	<ul style="list-style-type: none"> <li>Local or regional, affecting lymphatic drainage and regional nodes; podoconiosis-like with pigment obliteration, lymphedema or swollen nodes</li> </ul>
Tumours	<ul style="list-style-type: none"> <li>Keratoacanthoma, fibroma, pyogenic granuloma</li> <li>Malignant skin tumours, by coincidence</li> </ul>
Abnormal scarring	<ul style="list-style-type: none"> <li>By predisposition or as sequel of tattoo needle trauma/tattoo removal by lasers or caustic chemicals</li> </ul>
Tattoo pigment diffusion or fan	<ul style="list-style-type: none"> <li>Horizontal visible pigment propagation in skin or deeply into underlying structures. Also called 'blow out'</li> </ul>
Irritant and local toxic events	<ul style="list-style-type: none"> <li>Common during tattoo healing causing delayed healing but uncommon as a chronic event</li> </ul>
Tattoo technique failure and hazards, by mechanism	<ul style="list-style-type: none"> <li>Needle trauma with delayed healing, 'overworked tattoo', hooked needle</li> <li>Overdose of tattoo ink, inflammation, late healing and discharge of pigment to the skin surface</li> <li>Infections from identified source (needle, machine, inks)</li> </ul>
Tattoo removal failures and hazards, by mechanism and technique	<ul style="list-style-type: none"> <li>Incomplete tattoo removal by laser, Intense Pulsed Light (IPL), chemicals/caustics/dermabrasion/salabrasion</li> <li>Surgery complicated by infection, scar, dyspigmentation or defect left to heal per primam</li> </ul>
Miscellaneous	<ul style="list-style-type: none"> <li>Local events (pimples and other minor manifestations)</li> <li>Provocation of other diseases by tattooing (Köbner phenomenon in psoriasis)</li> </ul>
Psycho-social complications without and with associated psychiatric disease	<ul style="list-style-type: none"> <li>Tattoo regret ranging from mild to severe dissonance with society; tattooing of the face/neck/hands/genitals/eyes or covering extensive skin fields; motives that frighten</li> </ul>

been utilized in selected cases.<sup>38–41</sup> Tattoo-related allergies may also involve tattoo aftercare products or protective wear for the tattooist, such as latex gloves.<sup>42,43</sup>

Another frequent tattoo reaction is papulo-nodular granulomatous reaction primarily not only observed in black tattoos but also reported in blue and exceptionally in red tattoos.<sup>25,28,44</sup> These reactions are defined as chronic papules or nodules limited to the tattooed skin, therefore named papulo-nodular black tattoo reactions.<sup>25,28,44</sup> There are no clinical or histological signs of infection. The symptoms

are generally mild itch or pain. The onset of symptoms may vary from a few weeks to several years after tattooing. Histopathology shows granulomatous inflammation or multiple granulomas, which may be sarcoid. Involvement of other organs is reported in 15%–21%, including pulmonary sarcoidosis, uveitis and erythema nodosum.<sup>25,28,44–47</sup> Older black tattoos may be triggered by a more recent tattoo with papulo-nodular reaction and suddenly develop a similar pathology, the 'rush phenomenon'.<sup>28</sup> Therefore, with these reactions, screening for sarcoidosis is required. Uveitis may



occur as the sole complication to a granulomatous tattoo reaction and be recalcitrant.<sup>48</sup> Pulmonary affection and erythema nodosum also may be sole complications indicative of systemic sarcoidosis. Treatments include local corticosteroids and in advanced cases, especially if 'rush phenomenon' and systemic manifestation occur, oral prednisone, immunosuppressives or biologics.<sup>25,28,49</sup> The aetiology of these systemic reactions may be autoimmunity triggered by tattoo pigment. Pigment agglomeration is suggested as a possible pathomechanism.<sup>50,51</sup> Rarely, targeted therapies and immune checkpoint inhibitors are other suggested triggers.<sup>52</sup>

Also skin diseases like psoriasis vulgaris, lichen planus, cutaneous lupus erythematosus and vitiligo have been reported to be triggered by tattooing with debut of psoriasis directly in the tattoo or even widespread in the skin.<sup>53,54</sup> These skin manifestations may be induced by the needle trauma of the tattooing, causing an inflammatory response known as the Koebner phenomenon.<sup>55</sup>

Miscellaneous tattoo reactions include blow out, hypertrophic scarring, keloid formation, photosensitivity and neurosensory pain or itch. Despite the extensive cutaneous trauma of tattooing, only few cases of tattoo keloid have been reported.<sup>56</sup> Neurosensory tattoo reaction is a rare complication defined by a chronic neurogenic pain or itch in the absence of clinical or histological abnormalities.<sup>25</sup> Its pathomechanism is yet unknown. In terms of tattoo removal, laser-induced tattoo removal complications are hypo- or hyperpigmentation, blistering, scars, incomplete tattoo removal or paradoxical darkening. In dermatological practice, a rise of complications due to alternative tattoo removal approaches also has been observed.<sup>57</sup> These removal methods include caustic products and may cause severe ulceration, infection and scarring.

In a hospital setting, the vast majority of tattoo complications are chronic. Black and red tattoos are the most frequently involved, whereas green and blue tattoos represent, with 2%, only a small minority of the total of tattoo complications.<sup>28</sup> Dermatological practices have reported that the percentage of complications in PMU is relatively high with 7%. Tattoo removal-induced complications account for up to 6% of all tattoo complications.<sup>28</sup>

### Recent research on potential tattoo-related allergens

The first systematic study of 90 patients with allergic reactions in red tattoos came out with mostly negative patch test findings of a tattoo ink series, culprit inks delivered by patients, and the common standard battery including metals and preservatives.<sup>32</sup> Taken the period of months to years from the point at which the tattoo was made until the appearance of the tattoo allergy, it was concluded that the epitope or culprit allergen was likely to be formed from a chemical breakdown of the pigment becoming active through haptization. Thus, the pigment allergen was not present in the inks bottle. This along with questionable skin permeation of pigments marks severe methodological limitations of patch testing of tattoo

pigment allergies. Yet tape stripping and prolonged reading periods might improve diagnostic quality.<sup>58</sup>

In Germany's Information Network of Departments of Dermatology (IVDK) over 43,000 patients were patch tested between January 2017 and June 2021. Tattoos were increasingly mentioned as suspected allergens by 0.20% of the patients in 2017 and 0.43% in 2021.

Between August 2018 and July 2019, out of 57 tattooed patients, 32% were diagnosed with allergic contact dermatitis (ACD). Patch test results showed no significant differences in the proportions of positive reactions to metal salts between the tattooed and the non-tattooed population. Microbiological contamination of tattoo and PMU inks, which is favoured by the high content of organic substances and water and potentially occurring upon bottle opening, is commonly prevented by the addition of preservatives, up to concentrations of 1.5% by weight, to ink formulations.<sup>3</sup> Since preservatives are potential skin sensitizers or irritants, they may contribute to allergic reactions following tattoo or PMU application. For sensitization to methylisothiazolinone (MI) and formaldehyde, no significant differences between tattooed and non-tattooed individuals were found. Proportions of positive reactions to benzisothiazolinone (BIT) between tattooed and non-tattooed showed a noticeable, albeit not significant, increase in the tattooed group (6% vs. 3%). However, the clinical relevance of the observed positive reactions to BIT or nickel<sup>59</sup> remains questionable and should be re-evaluated in bigger cohorts.<sup>60</sup>

A recent study aimed to estimate the occurrence and the concentrations of 14 preservatives in 138 inks (99 tattoo and 39 PMU inks).<sup>61</sup> Isothiazolinone derivatives were the most frequently detected preservatives in both tattoo and PMU ink formulations. In particular, BIT was the most frequently detected isothiazolinone. Undisclosed use of preservatives was found to be frequent, since methylparaben, ethylparaben, BIT and other isothiazolinones were declared in none of the tested sample labels. Phenoxyethanol (PE) was found in 24 samples, out of which only 10 were labelled as containing PE. With reference to the country of origin of inks, BIT was detected only in those manufactured in the United States, whereas PE was present in both Italian and US inks.

In contrast to the implemented insoluble pigment dispersion, which is responsible for delayed, long-lasting, and elevated reaction patterns of patients, the easily soluble fraction of a tattoo ink is excreted within days or weeks from the body and may be the culprit of short-term eczematous, rash reactions in patients usually not consulting dermatological practices, particularly patients who were sensitized through other exposure before tattooing.<sup>62,63</sup>

### Tattoos and cancer

The risk of development of skin cancers on tattoos has been long feared.<sup>64</sup> A comprehensive review in 2012, which described the occurrence of skin cancer on tattoos as fortuitous,<sup>65</sup> has not been contradicted so far. While skin cancers



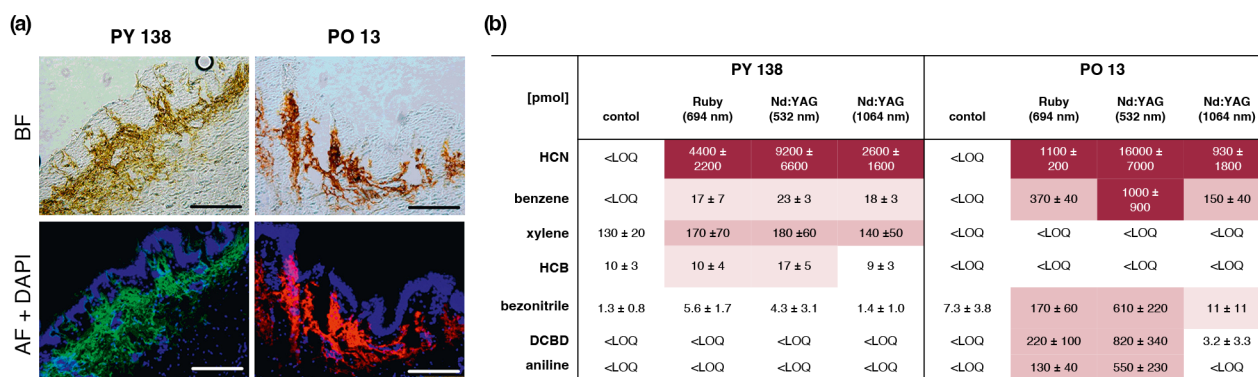
develop in the epidermis, for example basal cell carcinoma (BCC) in the epithelial basaloid cells and melanoma in the pigment-producing melanocytes, tattoo inks are generally injected into the deeper lying dermis with a different histological composition less associated with skin cancer development.<sup>8,66</sup> On the other hand, haematopoietic and lymphoid neoplasms arising in the T and B cells of the lymphatic system particularly regional lymph nodes, could be more likely candidates.<sup>67</sup> The number of case reports of skin cancers has increased but so has the number of tattooed individuals as well. Causality remains not documented. Only isolated case reports or limited series of cases of melanoma,<sup>68</sup> basal cell carcinomas<sup>69</sup> and squamous cell carcinomas<sup>70</sup> have been reported. Furthermore, the experience of tattoo clinics and consultations throughout Europe confirms that this type of event is exceptional.<sup>25,28,71–74</sup> However, keratoacanthoma, a rapidly growing tumour of debated malignancy can develop shortly after tattooing, usually within a few months after the tattoo was made. They may heal spontaneously despite sharing features of squamous cell carcinoma in histology. Lesions can be unique or multiple and eruptive, and they display a striking affinity for red-coloured tattoos. Other factors that could be involved in the pathophysiology of keratoacanthomas in tattoos include trauma and inflammation during the procedure, sun exposure during healing or tattooing on an area of prior chronic sun exposure. Moreover, patients developing these syndromes are usually older than those with tattoo allergies.<sup>70</sup> Studies of mice tattooed with black inks and subjected to UV irradiation have shown that the mice as expected developed light-induced skin cancer in normal skin, surprisingly, contrasting significantly fewer skin cancers in the tattooed skin, despite the presence of the polycyclic aromatic hydrocarbon (PAH) benzo(a)pyrene in the ink used for tattooing.<sup>75</sup> This may be attributed to the extraordinarily high molar absorptivity in the UV and visible ranges of PAHs. In a similar study with a red ink containing 2-anisidine and UV exposure, few skin cancers developed, but the co-carcinogenic effect was uncertain, since counting

of lesions also may have included keratoacanthomas, known to be associated with red pigments.<sup>76</sup>

Due to the transport of tattoo pigments, the exposure of the regional lymph nodes is of highest concern.<sup>12,77</sup> Although unknown, it appears plausible that this local exposure to pigment particles, particularly with metal content, could trigger an immune response in the lymph nodes as an effort to defend the body.<sup>78,79</sup> The defense efforts of the immune system could give rise to chronic inflammation, a mechanism closely linked to cancer development.<sup>8,80</sup> Since blood vessels are damaged during tattooing, some pigments may enter the blood stream. Primary aromatic amines (PAAs) as possible carcinogenic decomposition products of organic pigments and PAHs as possible impurities in organic pigments are of particular systemic concern.<sup>15,18,81,82</sup>

Several in vitro studies have shown the appearance of carcinogenic substances upon tattoo laser treatment. Therefore, the risk of skin cancers or inner organs cancers after such treatments remains of concern.<sup>22,24,83,84</sup> For example, decomposition products of an azo pigment (Pigment Orange (PO) 13) and a quinophthalone pigment (Pigment Yellow (PY) 138) were identified in tattooed pigskin upon irradiation with a Q-switched ruby and Nd:YAG laser (Figure 2).<sup>22</sup> Among others, the carcinogens hexachlorobenzene (HCB) and 3,3'-dichlorobenzidine (DCBD) were detected upon the laser treatment of PY 138 and PO 13, respectively. While HCB is a non-genotoxic carcinogen, DCBD induced DNA double-strand breaks at relevant concentrations.

To date, only two limited case-control studies have analysed the relationship between tattoos and cancer.<sup>85,86</sup> However, the results of these studies, both re-analyse case-control data collected (mostly) approx. 20 years ago, remain elusive due to major methodological limitations. However, there are recent advancements: To prospectively study the potential relationship between tattoos and cancer, the International Agency for Research on Cancer (IARC) and the German Cancer Research Center (DKFZ)



**FIGURE 2** (a) Pigskin tattooed with quinophthalone pigment yellow (PY 138) and the diazo pigment orange (PO 13) displayed as bright field (BF) and 4',6-diamidino-2-phenylindole (DAPI) staining of the cell nuclei with pigment autofluorescence (AF) (scale bar = 100 μm). (b) Laser decomposition products of the pigments upon irradiation of the pigskin with three laser wavelengths. The pink-coloured fields indicate the concentration of the detected products as for >10 pmol (bright), >100 pmol (middle), and >1000 pmol (dark). Hydrogen cyanide (HCN), hexachlorobenzene (HCB), 3,3'-dichlorobenzidine (DCBD), limit of quantification (LOQ).<sup>22</sup>

have set up a tattoo exposure collection in the French and German national cohorts, Constances and NAKO.<sup>87,88</sup> Each cohort enrolled approximately 200,000 individuals and collected detailed data on sociodemographic factors and potential confounders. Cohort participants are being followed up prospectively to compare the occurrence of certain diseases, including cancers, among the tattooed versus non-tattooed cohort participants.<sup>89</sup> Due to the large number of tattooed people followed in both cohorts (~30,000 combined), this approach will also allow assessment of dose–effect relationships. While the study design is scientifically sound, due to the low haematopoietic cancers incidence and a presumably long lag time, reliable results based on sufficiently large numbers are expected in 10–20 years only.

## RISK ASSESSMENT AND REGULATION OF TATTOO INKS: CHANCES AND CHALLENGES

### Gaining *in vitro*, human and *in silico* data on tattoo ink toxicology

Risk assessment in general is conducted by the combination of data on the inherent health hazards of a certain substance, product or mixture with data on human exposure. For tattooing, only limited exposure data exists.<sup>6,90,91</sup> In 2021, a short-term biokinetics study for soluble ink ingredients was conducted with human volunteers.<sup>92</sup> This study depicts a realistic exposure scenario and can be used to calculate the dose, that is the amount of ink per tattooed square centimetre. However, quantitative pigment distribution data would require first the development of analytical techniques for pigments in biological matrices followed by appropriate human or animal studies.

Data gaps also exist in terms of *in vitro* tests that can be used to assess possible toxicological effects of tattoo inks.<sup>93</sup> For soluble ingredients, Organisation for Economic Co-operation and Development (OECD) test guidelines and other standardized methods can be applied. Yet these were not designed to address the intradermal application route. Moreover, some of the most common adverse effects of tattoos, such as contact allergies, can to date not be linked to specific compounds or pigment properties.<sup>25,28,35</sup> Frequent side effects with unknown aetiology are photoreactions in tattoos after sun exposure.<sup>94</sup> Recently, the first model representing healed tattooed skin was developed.<sup>95</sup> Phagocytizing immune cells were incorporated into the model to resemble healed tattooed skin. In a proof-of-principle study, the model's applicability for phototoxicity testing was investigated.<sup>96</sup> Other commercial 3D models are helpful in investigating the general toxicity of tattoo inks during wound healing.<sup>97</sup> In some of these experiments tattoo inks were found to have a negative impact on cell viability. Application of *in silico* toxicity predictions in combination with existing *in vivo* and *in vitro* data needs to be evaluated regarding its suitability for tattoo ink risk

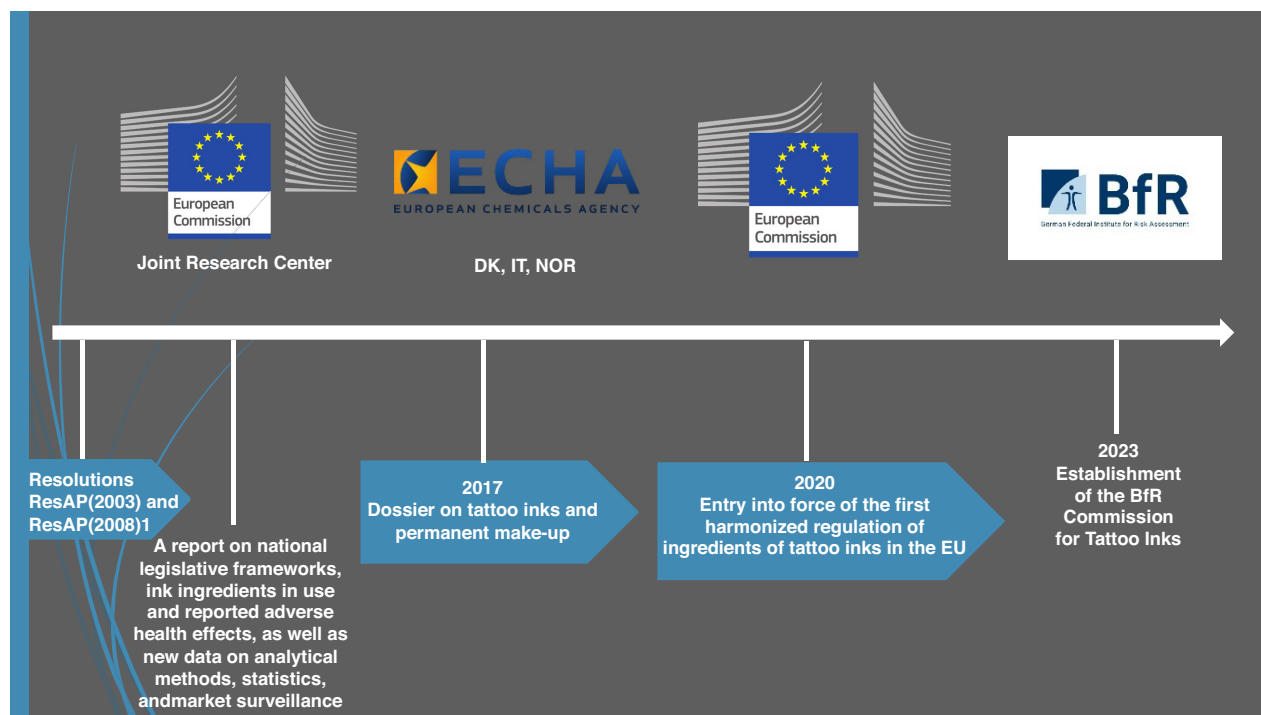
assessment, in particular for the identification of structural alerts and confirmation purposes.<sup>98</sup>

### Current regulations and future recommendation

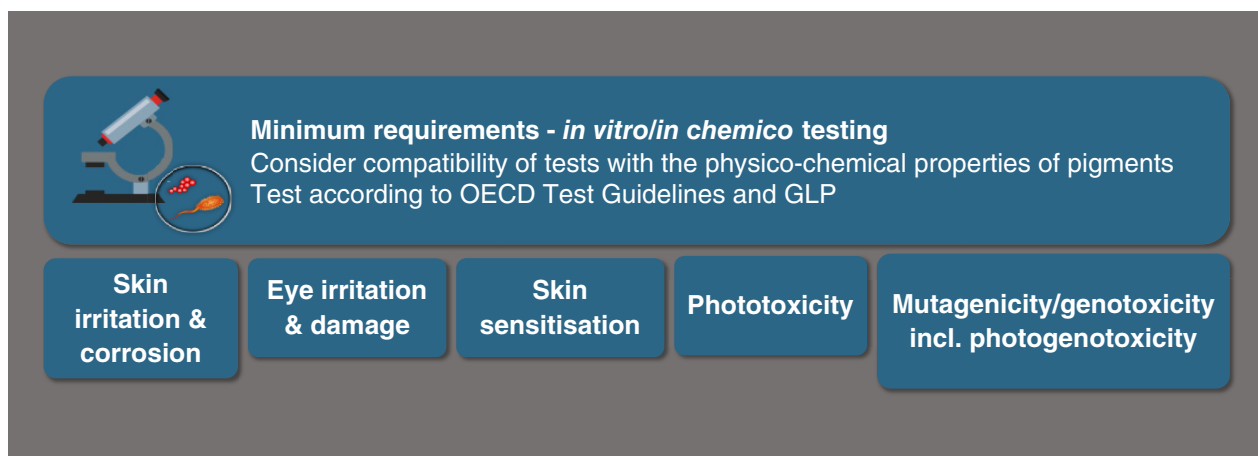
The growing popularity of tattoos and PMU over the past years, particularly in the young population, has increased concerns about the safety of tattoo inks.<sup>99</sup> In the EU, adopting the REACH restriction (entry No. 75, Annex XVII to Regulation (EC) No. 1907/2006) on substances in tattoo inks or PMU, aims to protect the health of EU citizens.<sup>100</sup> The restriction bans substances prohibited in cosmetic products, harmonized classified chemicals that are carcinogenic, mutagenic or toxic for reproduction, and substances causing skin sensitization, skin corrosion or irritation, and eye damage or irritation. Maximum concentration limits have been established for either groups or individual substances such as certain azo pigments and carcinogenic PAAs, PAHs, metals (As, Ba, Cd, Cr, Co, Cu, Zn, Pb, Se) and methanol. The restriction also provides harmonized labelling requirements to give consumers and tattooists additional information, facilitate the implementation of the restriction, prevent fragmentation of the internal market and ensure that investigations can be carried out properly in the event of adverse health effects. National laws within EU member states, for example in terms of labelling or sterilization requirements, may still apply additionally. The progress in regulatory activities in the EU and the development of risk assessment criteria for tattoo inks are depicted in Figure 3.

In the United States, tattoo inks meet the definition of cosmetics and tattoo pigments meet the definition of colour additives. Currently, no colour additives have been approved by the US Food and Drug Administration (FDA) for injection into the skin for cosmetic purposes, and no tattoo pigments have been approved by the FDA for use in tattoo inks. The FDA learns of problems with tattoo inks and pigments through adverse event reports that are received by the agency through its MedWatch system or the Center for Food Safety and Applied Nutrition's Adverse Event Reporting System (CAERS).

With the aim to improve consumer safety, the German Institute for Risk Assessment (BfR) has compiled a set of requirements and test methods.<sup>93</sup> These are intended to set the criteria for evaluating risks from tattoo inks and their ingredients according to the current state of science and technology. A series of OECD test guidelines were selected based on their potential suitability for testing tattoo pigments (Figure 4). Nonetheless, as pigments possess different solubilities and may contain a considerable fraction of nanomaterials, adaptations of the test guidelines have to be considered.<sup>101</sup> Potential effects of substances leaching under physiological conditions needs to be considered. Furthermore, tests based on epithelial cornea models or reconstructed human skin models require adaptations mimic a realistic exposure scenario, that is the placement of pigments into the dermis. Such models lack the mechanical injury of their barriers, which is typical for the tattooing procedure.



**FIGURE 3** Progress in regulation and risk assessment of tattoo inks in the EU. DK, Denmark; IT, Italy; NOR, Norway.<sup>3</sup>



**FIGURE 4** Selected endpoints for the toxicological assessment of tattoo pigments. GLP, good laboratory practice; OECD, Organisation for Economic Co-operation and Development.

## ANALYSIS OF TATTOO INK INGREDIENTS

### Statistical data on inks used in 2019: A historical benchmark

The leading Danish electronic registration system InkBase used by over 100 tattoo studios collected systematic information on approximately 40,000 tattoo clients, who were tattooed in around 50,000 sessions with over 110,000 different colours. The mean number of colours per client was 2.8. In 2019, 98% of inks were produced in the United States with

Eternal Ink, Fusion Ink, World Famous Ink, Intenze Ink and Dynamic Colours comprising 91% of the market. Despite the large number of registered inks, only 35 different pigments appeared on the bottle labels. The most frequently labelled pigments were: titanium dioxide (32%), carbon black (22%), Pigment Blue (PB) 15 (14%), Pigment Red (PR) 101 (6%), PR 170 (5%), Pigment Green (PG) 36 (5%), PO 13 (4%), PR 210 (4%), PY 14 (4%), PG 7 (1%) and Pigment Violet (PV) 37 (1%).

Yet, pigment labels do not necessarily represent the chemical composition of the inks. In a Swiss market surveillance study in the year 2020 with 85 tattoo inks, 19 samples (22%) contained one or more banned pigments in relevant

quantities (PG 7 (7%), PR 122 (6%), PR 112, PV 19, PV 23 and PY 83 (3%)).<sup>102</sup> Of these 23 instances, only two were correctly declared on the product label. In comparison, legal pigments which were not declared were only found in six samples. This indicates that manufacturers might be knowingly using clandestine pigments, especially for green, magenta and violet tattoo inks.

## Analysis of tattoo pigments

### Analysis of organic pigments and metallic impurities—Work in progress

Several methods for the identification of organic pigments in tattoo inks or biological specimens have been published.<sup>2,103–107</sup> The analytical methods used, Fourier transform infrared spectroscopy (FTIR), Raman spectroscopy, laser desorption/ionization–time of flight–mass spectrometry (LDI-ToF-MS) and pyrolysis gas chromatography–mass spectrometry (Py-GC-MS), seem less suited for quantitative analysis of pigments in inks, especially in complex mixtures or at levels below 0.1% as required by the REACH restriction.

The development of a quantitative determination of pigments by high-performance liquid chromatography (HPLC) was presented recently.<sup>108</sup> In this method a screening step is employed where small amounts of ink are extracted with small volumes of Dimethylformamide (DMF), N-methylpyrrolidone (NMP) and chloronaphthalene (CLN) each using an ultrasonic homogenizer. Mono azo pigments like PR 22 (C.I. 12,315), PR 210 (C.I. 12,477) or PY 74 (C.I. 11,741) are generally well extracted with DMF, whereas other pigments PV 19 (C.I. 73,900) or PR 122 (C.I. 73,915) are better extracted with NMP. Once extracted, samples are analysed by a standard reversed-phase HPLC method with photodiode array detection (DAD) using a C8 stationary phase and gradient elution with phosphate buffer pH 6, methanol and acetonitrile. This method was used to determine organic pigments in 64 tattoo ink samples from the Swiss market. An assessment based on the REACH regulation showed that 78% of the samples contained relevant levels of forbidden pigments.

Hazardous metals in tattoo inks can be analysed by total digestion of samples<sup>109</sup> and followed by determination of the metal concentrations.<sup>110</sup> Recently, analytical methods have been developed and validated for the measurement of metal and metal nanoparticles concentrations, average particle size and particle size distribution by using inductively coupled plasma mass spectrometry (ICP-MS) and ICP-MS coupled online with separation techniques and multiple detectors.<sup>111–114</sup> In particular, the presence of the metals Pb, Sb and Sn exceeded the set concentration limits under REACH. For the quantification of Cr(VI), an alkaline extraction of inks followed by ion chromatographic separation coupled to ICP-MS was developed and applied.<sup>114</sup> Results showed that 55% of the inks contained Cr(VI) exceeding the set limit.

In addition, a method using single particle ICP-MS (SP-ICP-MS) was developed for the counting and sizing of metal nanoparticles.<sup>112</sup> The study reported on several metals and metal oxides at nano- and micro-size ranges, with smaller particles found for Pb and Zn (27–38 nm), intermediate sizes for Cr and Cu (50–59 nm) and diameters between 100 and 300 nm for Al and Ti particles. Moreover, the online coupling of ICP-MS with asymmetric flow field fractionation and multi-angle light scattering (AF4-MALS-ICP-MS) was a powerful method for separation and the subsequent quantification of the metal nanoparticles.<sup>113</sup>

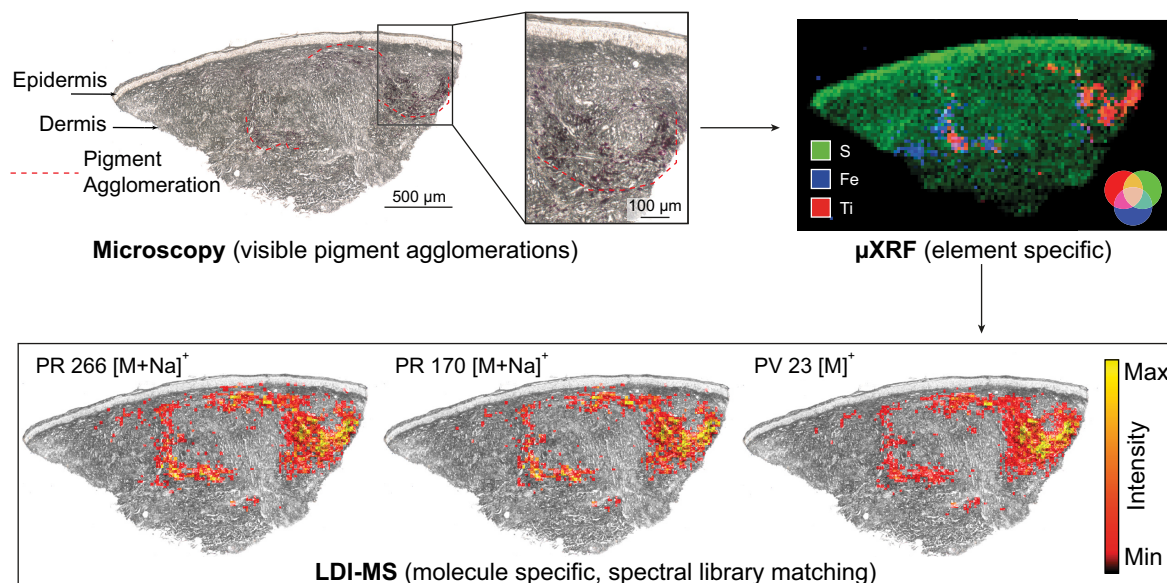
### Identifying tattoo pigments in human skin samples

When adverse skin reactions within the tattooed region occur, especially allergic reactions, histological findings should be accompanied by chemical analysis to detect possible culprit pigments.<sup>115</sup> A laser ablation (LA)-ICP-MS method was developed, and external calibration via matrix-matched standards was used to quantify metals directly in the tissue. Here, the spatial dimension allowed the differentiation from endogenous elements and the correlation of metal signals to visible pigment areas.<sup>116</sup> Additionally, X-ray fluorescence (XRF) was used to identify more abundant metals in skin and lymph node samples<sup>116,117</sup> while X-ray absorption near edge structure (XANES) analysis was capable of determining crystal structures of TiO<sub>2</sub>.<sup>34,117</sup>

Organic pigments in skin samples were previously identified by vibrational spectroscopy techniques, for example Raman spectroscopy<sup>103,118</sup> and FTIR.<sup>103,117</sup> These techniques were limited when pigment mixtures were assessed<sup>105</sup> or when more complex matrices, for example human tissue, were investigated.<sup>119</sup> Therefore, skin material was investigated by LDI-MS<sup>117</sup> and matrix-assisted LDI-MS (MALDI-MS)<sup>119</sup> after enzymatic digestion with collagenase and, subsequently, mechanical disruption. The addition of a highly absorbing matrix in MALDI enhanced signal intensities compared with LDI.<sup>119</sup>

Two recently published studies analysed the elemental and molecular composition of tattoo pigments in human skin samples with similar approaches.<sup>34,35</sup> In one study, conducting spatially resolved analysis, samples were taken as samples were taken as punch biopsies of adversely reacted tattooed areas (Figure 5). Initially,  $\mu$ XRF was used for rapid and non-destructive screening of characteristic elements of inorganic pigments and heteroatoms in organic pigments. LDI-MS and mass spectral library matching acquired molecular information. A comprehensive study of 68 skin samples resulted in the detection of the elements Ti and Fe as well as the pigments PR 122 (C.I. 73,915), PR 170 (C.I. 12,475), PR 266 (C.I. 12,474), PB 15 (C.I. 74,160) and PV 19 (C.I. 73,900). Frequent co-occurrences were observed for Ti and PR 122, as well as for PR 170 and PR 266. The latter can be explained by a commonly used pigment mixture, namely PR 210, containing both PR 170 and PR 266.





**FIGURE 5** Analysis of tattooed skin samples consists of three complementary imaging techniques for pigment identification. Visible pigment agglomerations are seen in the microscopic image, whereas elemental content, for example iron or titanium, and molecular information are collected by micro-X-ray fluorescence ( $\mu$ XRF) and laser desorption/ionization–mass spectrometry (LDI-MS), respectively. In  $\mu$ XRF analysis, sulphur (S) can be used to display the tissue structure, while iron (Fe) and titanium (Ti) occur as highly concentrated elements in inorganic pigments. Organic pigments are identified by mass spectral library matching after LDI-MS analysis. In the exemplary skin sample, the spatial distribution of sodium adducts ( $[M^+ Na]^+$ ) of Pigment Red (PR) 170 and PR 266, and the molecular ion ( $[M]^+$ ) of Pigment Violet (PV) 23 are displayed. The overlays of all images enable a comparison of the spatial localization and validation of the pigment annotation.

The possibilities of using Raman spectroscopy to determine tattoo pigments and its use as a screening tool for diagnostics of tattoo complications were demonstrated as well.<sup>120</sup> This non-destructive method can be used for *in vivo* measurements while maintaining a safe radiation power level. By using tissue phantoms, mimicking the skin optical properties, it is possible to investigate the light scattering behaviour on various samples. Moreover, due to their tunability, tissue phantoms can be used to calibrate optical measurements of substances in the skin.<sup>120–122</sup>

## CONCLUSIONS

Medical-toxicological insights of tattoo complications as well as the preventions of risks remain despite better knowledge today hampered by huge knowledge gaps with respect to clinical, epidemiological, chemical, physical, toxicological and experimental research. The research field is highly complicated and faceted. Tattoo inks are industrial products with many impurities and contaminants and major variations between brands, batches and particles. The field is severely under-researched. Tattooing is performed by single dose injection in skin of robust and insoluble physical pigment particles. Their slow breakdown with chemicals released to the body over years has found no valid toxicological model for the study of the biokinetics of this extraordinary dosage form and the long-term exposure of risk organs. Toxicological standard models to characterize potential risks such as carcinogenicity, potential for allergic

sensitization and photosensitivity are primarily applied to soluble substances and not directly applicable to tattoo inks and tattoo pigments. Thus, an algorithm for tattoo ink product assessment is not on hand, and surveillance strategies to register and limit risks of tattooing should be further developed and forcefully instituted since hundreds of millions of world citizens are exposed.

## SEARCH STRATEGY AND SELECTION CRITERIA

Data for this review were identified by searches PubMed and references from relevant articles using the search terms “tattoo”, “tattoo inks”, and “tattoo pigments”. Reports from meetings were included only when they related directly to previously published work.

## AUTHOR CONTRIBUTIONS

All authors contributed equally to this manuscript.

## AFFILIATIONS

<sup>1</sup>Department of Chemical and Product Safety, German Federal Institute for Risk Assessment (BfR), Berlin, Germany

<sup>2</sup>Department of Environment and Health, Istituto Superiore di Sanità (ISS), Rome, Italy

<sup>3</sup>Department of Dermatology, University of Regensburg, Regensburg, Germany

<sup>4</sup>European Commission, DG Internal Market, Industry, Entrepreneurship and SMEs (GROW), Brussels, Belgium

<sup>5</sup>Institute of Inorganic and Analytical Chemistry, University of Münster, Münster, Germany

<sup>6</sup>National Centre for Chemicals, Cosmetic Products and Consumer's Health Protection - Istituto Superiore di Sanità (ISS), Rome, Italy

<sup>7</sup>Environment and Lifestyle Epidemiology Branch, International Agency for Research on Cancer (IARC), Lyon, France

<sup>8</sup>Karlsruhe Chemical and Veterinary Investigation Authority, Karlsruhe, Germany

<sup>9</sup>CTL GmbH Bielefeld, Bielefeld, Germany

<sup>10</sup>Kanton Basel-Stadt, Kantonales Laboratorium, Basel, Switzerland

<sup>11</sup>Department of Metrology and Optoelectronics, Faculty of Electronics, Telecommunication, and Informatics, Gdansk University of Technology, Gdansk, Poland

<sup>12</sup>Office of Cosmetics and Colors, United States Food and Drug Administration (FDA), College Park, Maryland, USA

<sup>13</sup>Department of Dermatology, Helsinki University Hospital and University of Helsinki, Helsinki, Finland

<sup>14</sup>“Tattoo Consultation”, Department of Dermatology, Bichat – Claude Bernard Hospital, Paris, France

<sup>15</sup>EADV Tattoo and Body Art Task Force, Lugano, Switzerland

<sup>16</sup>Department of Dermatology, the Tattoo Clinic, Bispebjerg University Hospital, Copenhagen, Denmark

<sup>17</sup>Information Network of Departments of Dermatology – IVDK, Institute at the University Medical Center Göttingen, Göttingen, Germany

<sup>18</sup>Tattoo Clinic (Tattoo Poli), Department of Dermatology, Alrijne Hospital, Leiden, CK, The Netherlands

## ACKNOWLEDGEMENTS

The writing of this Review and the realisation of the 2nd International Conference on Tattoo Safety at the German Federal Institute for Risk Assessment (BfR) in 2021 has been financially supported by intramural grants of the BfR. Open Access funding enabled and organized by Projekt DEAL.

## FUNDING INFORMATION

None.

## CONFLICT OF INTEREST STATEMENT

All authors declare no conflict of interests.

## DISCLAIMER

Where authors are identified as personnel of the International Agency for Research on Cancer/World Health Organization, the authors alone are responsible for the views expressed in this article and they do not necessarily represent the decisions, policy or views of the International Agency for Research on Cancer/World Health Organization.

## DATA AVAILABILITY STATEMENT

Data sharing is not applicable to this article as no data sets were generated or analysed during the current study.

## ETHICS STATEMENT

The patients in this manuscript have given written informed consent to publication of their case details.

## ORCID

Michael Giulbudagian  <https://orcid.org/0000-0002-0832-8831>

Nicolas Kluger  <https://orcid.org/0000-0002-5225-8316>

Ines Schreiver  <https://orcid.org/0000-0001-9313-7193>

Steffen Schubert  <https://orcid.org/0000-0002-2359-2518>

## REFERENCES

1. Laux P, Tralau T, Tentschert J, Blume A, Al Dahouk S, Bäuml W, et al. A medical-toxicological view of tattooing. *Lancet*. 2016;387(10016):395–402.

2. Baumler W, Eibler ET, Hohenleutner U, Sens B, Sauer J, Landthaler M. Q-switch laser and tattoo pigments: first results of the chemical and photophysical analysis of 41 compounds. *Lasers Surg Med*. 2000;26(1):13–21.
3. Piccinini P, Pakalin S, Contor L, Bianchi I, Senaldi C. Safety of tattoos and permanent make-up final report. Joint Research Centre (European Commission): Publications Office of the European Union; 2016.
4. Rittie L. Cellular mechanisms of skin repair in humans and other mammals. *J Cell Commun Signal*. 2016;10(2):103–20.
5. Rittie L, Sachs DL, Orringer JS, Voorhees JJ, Fisher GJ. Eccrine sweat glands are major contributors to Reepithelialization of human wounds. *Am J Pathol*. 2013;182(1):163–71.
6. Engel E, Santarelli F, Vasold R, Maisch T, Ulrich H, Prantl L, et al. Modern tattoos cause high concentrations of hazardous pigments in skin. *Contact Dermatit*. 2008;58(4):228–33.
7. Ferguson JE, Andrew SM, Jones CJ, August PJ. The Q-switched neodymium:YAG laser and tattoos: a microscopic analysis of laser-tattoo interactions. *Br J Dermatol*. 1997;137(3):405–10.
8. Baranska A, Shawket A, Jouve M, Baratin M, Malosse C, Voluzan O, et al. Unveiling skin macrophage dynamics explains both tattoo persistence and strenuous removal. *J Exp Med*. 2018;215(4):1115–33.
9. Baumler W. Chemical hazard of tattoo colorants. *Presse Med*. 2020;49(4):104046.
10. Baumler W. Absorption, distribution, metabolism and excretion of tattoo colorants and ingredients in mouse and man: the known and the unknown. *Curr Probl Dermatol*. 2015;48:176–84.
11. Kluger N, Koljonen V. The surgeon, the tattoo and the black lymph node. *J Plast Reconstr Aesthet Surg*. 2013;66(4):561–2.
12. Lehner K, Santarelli F, Vasold R, Penning R, Sidoroff A, König B, et al. Black tattoos entail substantial uptake of genotoxic polycyclic aromatic hydrocarbons (PAH) in human skin and regional lymph nodes. *PLoS One*. 2014;9(3):e92787.
13. Sokolovskaya E, Shariff Y. Calcifications in axillary lymph nodes on negative mammograms: tattoo pigment mimicking axillary lymph node calcifications. *Breast J*. 2015;21(6):678–9.
14. Kreyling WG, Holzwarth U, Haberl N, Kozempel J, Hirn S, Wenk A, et al. Quantitative biokinetics of titanium dioxide nanoparticles after intravenous injection in rats: part 1. *Nanotoxicology*. 2017;11(4):434–42.
15. Umbreit TH, Francke-Carroll S, Weaver JL, Miller TJ, Goering PL, Sadrieh N, et al. Tissue distribution and histopathological effects of titanium dioxide nanoparticles after intravenous or subcutaneous injection in mice. *J Appl Toxicol*. 2012;32(5):350–7.
16. Xu J, Shi H, Ruth M, Yu H, Lazar L, Zou B, et al. Acute toxicity of intravenously administered titanium dioxide nanoparticles in mice. *PLoS One*. 2013;8(8):e70618.
17. Sonavane G, Tomoda K, Makino K. Biodistribution of colloidal gold nanoparticles after intravenous administration: effect of particle size. *Colloids Surf B Biointerfaces*. 2008;66(2):274–80.
18. Sepehri M, Sejersen T, Qvortrup K, Lerche CM, Serup J. Tattoo pigments are observed in the Kupffer cells of the liver indicating blood-borne distribution of tattoo ink. *Dermatology*. 2017;233(1):86–93.
19. Baumler W, Weiss KT. Laser assisted tattoo removal - state of the art and new developments. *Photochem Photobiol Sci*. 2019;18(2):349–58.
20. Engel E, Spannberger A, Vasold R, König B, Landthaler M, Baumler W. Photochemical cleavage of a tattoo pigment by UVB radiation or natural sunlight. *J Dtsch Dermatol Ges*. 2007;5(7):583–9.
21. Cui YY, Spann AP, Couch LH, Gopee NV, Evans FE, Churchwell MI, et al. Photodecomposition of pigment yellow 74, a pigment used in tattoo inks. *Photochem Photobiol*. 2004;80(2):175–84.
22. Hering H, Sung AY, Roder N, Hutzler C, Berlien HP, Laux P, et al. Laser irradiation of organic tattoo pigments releases carcinogens with 3,3'-Dichlorobenzidine inducing DNA Strand breaks in human skin cells. *J Invest Dermatol*. 2018;138(12):2687–90.

23. Schreiber I, Hutzler C, Laux P, Berlien HP, Luch A. Formation of highly toxic hydrogen cyanide upon ruby laser irradiation of the tattoo pigment phthalocyanine blue. *Sci Rep-UK*. 2015;5:5.
24. Vasold R, Naarmann N, Ulrich H, Fischer D, König B, Landthaler M, et al. Tattoo pigments are cleaved by laser light - the chemical analysis in vitro provide evidence for hazardous compounds. *Photochem Photobiol*. 2004;80(2):185–90.
25. Serup J, Sepehri M, Hutton CK. Classification of tattoo complications in a hospital material of 493 adverse events. *Dermatology*. 2016;232(6):668–78.
26. Diagnosis and therapy of tattoo complications: with atlas of illustrative cases. Berlin: S.Karger AG; 2017.
27. Huisman S, van der Bent SAS, Maijer KI, Tio DCKS, Rustemeyer T. Cutaneous non-allergic complications in tattoos: an overview of the literature. *Presse Med*. 2020;49(4):104049.
28. van der Bent SAS, Rauwerdink D, Oyen EMM, Maijer KI, Rustemeyer T, Wolkerstorfer A. Complications of tattoos and permanent makeup: overview and analysis of 308 cases. *J Cosmet Dermatol*. 2021;20(11):3630–41.
29. van der Bent SAS, de Winter RW, Wolkerstorfer A, Rustemeyer T. Red tattoo reactions, a prospective cohort on clinical aspects. *J Eur Acad Dermatol Venereol*. 2019;33(10):e384–e386.
30. van der Bent SAS, Oyen E, Rustemeyer T, Jaspars L, Hoekzema R. Histopathology of red tattoo reactions. *Am J Dermatopathol*. 2021;43(5):331–7.
31. Hogsberg T, Thomsen BM, Serup J. Histopathology and immune histochemistry of red tattoo reactions. Interface dermatitis is the lead pathology, with increase in T-lymphocytes and Langerhans cells suggesting an allergic pathomechanism. *Skin Res Technol*. 2015;21(4):449–58.
32. Serup J, Hutton CK. Patch test study of 90 patients with tattoo reactions: negative outcome of allergy patch test to baseline batteries and culprit inks suggests allergen(s) are generated in the skin through haptization. *Contact Dermatitis*. 2014;71(5):255–63.
33. Bil W, van der Bent SAS, Spiekstra SW, Nazmi K, Rustemeyer T, Gibbs S. Comparison of the skin sensitization potential of 3 red and 2 black tattoo inks using interleukin-18 as a biomarker in a reconstructed human skin model. *Contact Dermatitis*. 2018;79(6):336–45.
34. Serup J, Hutton Carlsen K, Dommershausen N, Sepehri M, Hesse B, Seim C, et al. Identification of pigments related to allergic tattoo reactions in 104 human skin biopsies. *Contact Dermatitis*. 2020;82(2):73–82.
35. Brungs C, Schmid R, Wolf C, Berg T, Korf A, Heuckeroth S, et al. Tattoo pigment identification in inks and skin biopsies of adverse reactions by complementary elemental and molecular bioimaging with mass spectral library matching. *Anal Chem*. 2022;94(8):3581–9.
36. van der Bent SAS, Huisman S, Rustemeyer T, Wolkerstorfer A. Ablative laser surgery for allergic tattoo reactions: a retrospective study. *Lasers Med Sci*. 2021;36(6):1241–8.
37. Sepehri M, Jørgensen B, Serup J. Introduction of dermatome shaving as first line treatment of chronic tattoo reactions. *J Dermatolog Treat*. 2015;26(5):451–5.
38. Godinho MM, Aguinaga F, Grynszpan R, Lima VM, Azulay DR, Cuzzi T, et al. Granulomatous reaction to red tattoo pigment treated with allopurinol. *J Cosmet Dermatol*. 2015;14(3):241–5.
39. de Winter RW, van der Bent SAS, van Esch M, Wolkerstorfer A, Rustemeyer T. Allergic reaction to red cosmetic lip tattoo treated with hydroxychloroquine. *Dermatitis*. 2019;30(1):82–3.
40. Martín JM, Revert A, Monteagudo C, Villalón G, Godoy R, Jordá E. Granulomatous reactions to permanent cosmetic tattoos successfully treated with topical steroids and allopurinol. *J Cosmet Dermatol*. 2007;6(4):229–31.
41. van der Bent SAS, van Doorn MBA. Treatment of a refractory allergic reaction to a red tattoo on the lips with methotrexate and Q-switched Nd-Yag laser. *JAAD Case Rep*. 2022;21:109–11.
42. Bregnbak D, Johansen JD, Zachariae C. Contact dermatitis caused by panthenol used for aftercare treatment of a new tattoo. *Contact Dermatitis*. 2016;75(1):50–2.
43. Hutton Carlsen K, Serup J. Tattooing may cause life-threatening latex allergy. *J Eur Acad Dermatol Venereol*. 2016;30(7):1242–4.
44. Sepehri M, Hutton Carlsen K, Serup J. Papulo-nodular reactions in black tattoos as markers of sarcoidosis: study of 92 tattoo reactions from a hospital material. *Dermatology*. 2016;232(6):679–86.
45. Kluger N. sarcoidosis on tattoos: a review of the literature from 1939 to 2011. *Sarcoidosis Vasc Diffuse Lung Dis*. 2013;30(2):86–102.
46. Huisman S, van der Bent SAS, Wolkerstorfer A, Rustemeyer T. Granulomatous tattoo reactions in permanent makeup of the eyebrows. *J Cosmet Dermatol*. 2019;18(1):212–4.
47. van der Bent SAS, Engel MJC, Nossent EJ, Jonkers RE, Wolkerstorfer A, Rustemeyer T. Tattoos and self-reported adverse events in sarcoidosis patients. *J Eur Acad Dermatol Venereol*. 2020;34(4):e167–e169.
48. Kluger N. Tattoo-associated uveitis with or without systemic sarcoidosis: a comparative review of the literature. *J Eur Acad Dermatol Venereol*. 2018;32(11):1852–61.
49. Maijer KI, van der Bent SAS, Vercoutere W, Rustemeyer T. Granulomatous tattoo reaction with associated uveitis successfully treated with methotrexate. *J Eur Acad Dermatol Venereol*. 2018;32(9):e338–e339.
50. Hutton Carlsen K, Larsen G, Serup J. Tattoo pigment agglomerates measured in skin biopsies by computerised light microscopy: study of 161 patients with adverse reactions in black and red tattoos. *Skin Res Technol*. 2020;26(2):284–91.
51. Hutton Carlsen K, Larsen G, Serup J. Tattoo pigment agglomerates measured in commercial ink stock products by computerised light microscopy. *Skin Res Technol*. 2020;26(2):292–300.
52. Kluger N. Tattoo reactions associated with targeted therapies and immune checkpoint inhibitors for advanced cancers: a brief review. *Dermatology*. 2019;235(6):522–4.
53. van der Bent SAS, Wolkerstorfer A, Rustemeyer T. Cutaneous adverse reactions to tattoos. *Ned Tijdschr Geneesk*. 2016;160(29):525–36.
54. Grodner C, Beauchet A, Fougereuse AC, Quiles-Tsimitaratos N, Perrot JL, Barthelemy H, et al. Tattoo complications in treated and non-treated psoriatic patients. *J Eur Acad Dermatol Venereol*. 2020;34(4):888–96.
55. Giet G, Senterre Y, Lebas E, Libon F, Dezfoulian B, Nikkels AF. Köbner's phenomenon in dermatology. *Rev Med Liege*. 2021;76(9):651–6.
56. Kluger N, Bosonnet S. Keloid occurring in a tattoo. *Ann Dermatol Venereol*. 2017;144(6–7):455.
57. Hutton Carlsen K, Serup J. Sequels to tattoo removal by caustic products. *Skin Res Technol*. 2018;24(4):636–41.
58. Schubert S, Kluger N, Schreiber I. Hypersensitivity to permanent tattoos: literature summary and comprehensive review of patch tested tattoo patients 1997–2022. *Contact Dermatitis*. 2023;88(5):331–50.
59. Schubert S, Dirks M, Dickel H, Lang C, Geier J, IVDK. Allergens in permanent tattoo ink - first results of the information network of departments of dermatology (IVDK). *J Dtsch Dermatol Ges*. 2021;19(9):1337–40.
60. Herman A, Aerts O, de Montjoye L, Tromme I, Goossens A, Baeck M. Isothiazolinone derivatives and allergic contact dermatitis: a review and update. *J Eur Acad Dermatol Venereol*. 2019;33(2):267–76.
61. Famele M, Lavalle R, Leoni C, Majorani C, Ferranti C, Palleschi L, et al. Quantification of preservatives in tattoo and permanent make-up inks in the frame of the new requirements under the REACH regulation. *Contact Dermatitis*. 2022;87(3):233–40.
62. Körner R, Pfohler C, Vogt T, Müller CS. Histopathology of body art revisited - analysis and discussion of 19 cases. *J Dtsch Dermatol Ges*. 2013;11(11):1073–80.
63. Serup J. Atlas of illustrative cases of tattoo complications. *Curr Probl Dermatol*. 2017;52:139–229.
64. Goldstein N. Tattoos today: from eyelids to ankles and some in '3-D'. *Arch Dermatol*. 1985;121(5):604–5.
65. Kluger N, Koljonen V. Tattoos, inks, and cancer. *Lancet Oncol*. 2012;13(4):e161–e168.



66. Didona D, Paolino G, Bottoni U, Cantisani C. Non melanoma skin cancer pathogenesis overview. *Biomedicine*. 2018;6(1):6.
67. Cerhan JR, Vajdic CM, Spinelli JJ. *The non-hodgkin lymphomas*. Schottenfeld and Fraumeni cancer epidemiology and prevention. 4th ed. Oxford: Oxford University Press; 2017. p. 767–96.
68. Cherkaoui El Baraka F, Kluger N, Ollivier I, Bourgoin R, Grossin M, Zeboulon C, et al. Melanoma within tattoos: two cases and a systematic literature review. *Ann Dermatol Venereol*. 2020;147(4):285–92.
69. Abudu B, Erickson CP, Calame A, Cohen PR. Basal cell carcinoma originating in a tattoo: case report and review of an uncommon complication in tattoo recipients. *Dermatol Pract Concept*. 2019;9(4):265–70.
70. Kluger N, Cribier B. Keratoacanthomas and squamous cell carcinomas on tattoos: a review of 42 cases. *Dermatology*. 2021;237(2):309–12.
71. Kluger N. Cutaneous complications related to tattoos: 31 cases from Finland. *Dermatology*. 2017;233(1):100–9.
72. Kluger N, Descamps V. Usefulness of a specialized «tattoo» consultation in a tertiary care hospital: a one-year experience. *J Eur Acad Dermatol Venereol*. 2019;33(4):e182–e183.
73. Kluger N. Cutaneous complications after tattooing in Finland from 2016 to 2021. *J Eur Acad Dermatol Venereol*. 2022;36(1):e72–e73.
74. Rogowska P, Sobjanek M, Sławińska M, Nowicki RJ, Szczerkowska-Dobosz A. Tattoos dermatological complications: analysis of 53 cases from northern Poland. *Dermatology*. 2021;1-8:799–806.
75. Lerche CM, Sepelhi M, Serup J, Poulsen T, Wulf HC. Black tattoos protect against UVR-induced skin cancer in mice. *Photodermatol Photoimmunol Photomed*. 2015;31(5):261–8.
76. Lerche CM, Heerfordt IM, Serup J, Poulsen T, Wulf HC. Red tattoos, ultraviolet radiation and skin cancer in mice. *Exp Dermatol*. 2017;26(11):1091–6.
77. Lehner K, Santarelli F, Penning R, Vasold R, Engel E, Maisch T, et al. The decrease of pigment concentration in red tattooed skin years after tattooing. *J Eur Acad Dermatol Venereol*. 2011;25(11):1340–5.
78. Iannitti T, Capone S, Gatti A, Capitani F, Cetta F, Palmieri B. Intracellular heavy metal nanoparticle storage: progressive accumulation within lymph nodes with transformation from chronic inflammation to malignancy. *Int J Nanomedicine*. 2010;5:955–60.
79. Devic J, Dussol M, Collin-Faure V, Pérard J, Fenel D, Schoehn G, et al. Immediate and sustained effects of cobalt and zinc-containing pigments on macrophages. *Front Immunol*. 2022;13:865239.
80. Murata M. Inflammation and cancer. *Environ Health Prev Med*. 2018;23(1):50.
81. IARC. Some aromatic amines, organic dyes, and related exposures. Lyon, France: IARC Press, International Agency for Research on Cancer; 2010.
82. Sabbioni G, Hauri U. Carcinogenic tattoos? *Epidemiol Biostat Public Health*. 2016;13(4):e12018-3.
83. Bauer EM, Scibetta EV, Cecchetti D, Piccirillo S, Antonaroli S, Sennato S, et al. Treatments of a phthalocyanine-based green ink for tattoo removal purposes: generation of toxic fragments and potentially harmful morphologies. *Arch Toxicol*. 2020;94(7):2359–75.
84. Kluger N, Badawi A, Laubach H-J, Wolkerstorfer A, Cartier H. Laser tattoo removal and risks of cancer: a joint statement of the EADV tattoo and body art task force, European Society for Lasers and Energy-Based Devices (ESLD) and la Société Française des lasers en Dermatologie. *J Eur Acad Dermatol Venereol*. 2023;37:e1354–e1355.
85. Warner FM, Darvishian M, Boyle T, Brooks-Wilson AR, Connors JM, Lai AS, et al. Tattoos and hematologic malignancies in British Columbia, Canada. *Cancer Epidemiol Biomarkers Prev*. 2020;29(10):2093–5.
86. Barton DT, Zens MS, Marmarelis EL, Gilbert-Diamond D, Karagas MR. Cosmetic tattooing and early onset basal cell carcinoma: a population-based case-control study from New Hampshire. *Epidemiology*. 2020;31(3):448–50.
87. Zins M, Bonenfant S, Carton M, Coeuret-Pellicier M, Guéguen A, Gourmelon J, et al. The CONSTANCES cohort: an open epidemiological laboratory. *BMC Public Health*. 2010;10(1):479.
88. The National Cohort. A prospective epidemiologic study resource for health and disease research in Germany. 2011.
89. Foerster M, Dufour L, Bäumler W, Schreiber I, Goldberg M, Zins M, et al. Development and validation of the epidemiological tattoo assessment tool to assess ink exposure and related factors in tattooed populations for medical research: Cross-sectional validation study. *JMIR Form Res*. 2023;7:e42158.
90. Arbache S, Mattos EDC, Diniz MF, Paiva PYA, Roth D, Arbache ST, et al. How much medication is delivered in a novel drug delivery technique that uses a tattoo machine? *Int J Dermatol*. 2019;58(6):750–5.
91. Butterfield JL, Keyser SP, Dikshit KV, Kwon H, Koster MI, Bruns CJ. Solar freckles: long-term photochromic tattoos for intradermal ultraviolet radiometry. *ACS Nano*. 2020;14(10):13619–28.
92. Schreiber I. *Bioavailability of tattoo inks by quantifying the marker substances 4-aminobenzoic acid, 2-phenoxyethanol and iodide in blood and urine after tattooing 24 male test persons with black or red color*. German Clinical Trials Register 2021.
93. BfR. Tattoo inks: minimum requirements and test methods. German Federal Institute for Risk Assessment 2021.
94. Hutton Carlsen K, Serup J. Photosensitivity and photodynamic events in black, red and blue tattoos are common: A 'Beach Study'. *J Eur Acad Dermatol Venereol*. 2014;28(2):133–262.
95. Hering H, Zoschke C, Kühn M, Gadicherla AK, Weindl G, Luch A, et al. TatS: a novel in vitro tattooed human skin model for improved pigment toxicology research. *Arch Toxicol*. 2020;94(7):2423–34.
96. Hering H, Zoschke C, König F, Kuhn M, Luch A, Schreiber I. Phototoxic versus photoprotective effects of tattoo pigments in reconstructed human skin models: in vitro phototoxicity testing of tattoo pigments: 3D versus 2D. *Toxicology*. 2021;460:152872.
97. Karregat JJJ, Rustemeyer T, van der Bent SAS, Spiekstra SW, Thon M, Fernandez Rivas D, et al. Assessment of cytotoxicity and sensitization potential of intradermally injected tattoo inks in reconstructed human skin. *Contact Dermatitis*. 2021;85(3):324–39.
98. Johnson C, Anger LT, Benigni R, Bower D, Bringezu F, Crofton KM, et al. Evaluating confidence in toxicity assessments based on experimental data and in silico predictions. *Comput Toxicol*. 2022;21:21.
99. Laux P, Luch A. The European landscape of national regulations of tattoo inks and businesses. *Curr Probl Dermatol*. 2015;48:196–200.
100. COMMISSION REGULATION (EU) 2020/2081, of 14 December 2020 amending Annex XVII to Regulation (EC) No 1907/2006 of the European Parliament and of the Council concerning the Registration, Evaluation, Authorisation and Restriction of Chemicals (REACH) as regards substances in tattoo inks or permanent make-up.
101. Stratmann H, Hellmund M, Veith U, End N, Teubner W. Indicators for lack of systemic availability of organic pigments. *Regul Toxicol Pharmacol*. 2020;115:104719.
102. Hauri U. Preservatives, colourants, primary aromatic amines, polyaromatic hydrocarbons and nitrosamines. Joint market surveillance of inks for tattoos and permanent make-up of the cantons Aargau, Bern, St. Gallen, Thurgau and Basel-City (focus laboratory). 2020.
103. Poon KWC, Dadour IR, McKinley AJ. In situ chemical analysis of modern organic tattooing inks and pigments by micro-Raman spectroscopy. *J Raman Spectrosc*. 2008;39(9):1227–37.
104. Hutton Carlsen K, Køcks M, Sepelhi M, Serup J. Allergic reactions in red tattoos: Raman spectroscopy for 'fingerprint' detection of chemical risk spectra in tattooed skin and culprit tattoo inks. *Skin Res Technol*. 2016;22(4):460–9.
105. Niederer M, Hauri U, Kroll L, Hohl C. Identification of organic pigments in tattoo inks and permanent make-up using laser desorption ionisation mass spectrometry. *F1000Res*. 2017;6:2034.
106. Schreiber I, Hutzler C, Andree S, Laux P, Luch A. Identification and hazard prediction of tattoo pigments by means of pyrolysis-gas chromatography/mass spectrometry. *Arch Toxicol*. 2016;90(7):1639–50.
107. Yakes BJ, Michael TJ, Perez-Gonzalez M, Harp BP. Investigation of tattoo pigments by Raman spectroscopy. *J Raman Spectrosc*. 2017;48(5):736–43.



108. Hauri U. Semi-quantitative analysis of organic pigments in tattoo inks with HPLC. BfR conference: challenges in public health protection in the 21st century: 2nd international conference on tattoo safety. Berlin, Germany: German Federal Institute for Risk Assessment; 2021.
109. Druckaufschluss zur Bestimmung von Elementen in kosmetischen Mitteln und Tätowiermitteln. BVL – Bundesamt für Verbraucherschutz Und Lebensmittelsicherheit. 2016.
110. Bestimmung von Barium, Nickel und anderen Elementen in kosmetischen Mitteln und Tätowiermitteln mittels optischer Emissionsspektroskopie mit induktiv gekoppeltem Plasma (ICP-OES) nach Druckaufschluss. BVL – Bundesamt für Verbraucherschutz Und Lebensmittelsicherheit. 2021.
111. Forte G, Petrucci F, Cristaudo A, Bocca B. Market survey on toxic metals contained in tattoo inks. *Sci Total Environ*. 2009;407(23):5997–6002.
112. Battisini B, Petrucci F, De Angelis I, Failla CM, Bocca B. Quantitative analysis of metals and metal-based nano- and submicron-particles in tattoo inks. *Chemosphere*. 2020;245:125667.
113. Bocca B, Sabbioni E, Mičetić I, Alimonti A, Petrucci F. Size and metal composition characterization of nano- and microparticles in tattoo inks by a combination of analytical techniques. *J Anal At Spectrom*. 2017;32(3):616–28.
114. Bocca B, Senofonte O, Petrucci F. Hexavalent chromium in tattoo inks: dermal exposure and systemic risk. *Contact Dermatitis*. 2018;79(4):218–25.
115. Weiß KT, Schreiber I, Siewert K, Luch A, Haslböck B, Berneburg M, et al. Tattoos – more than just colored skin? Searching for tattoo allergens. *J Dtsch Dermatol Ges*. 2021;19(5):657–69.
116. van der Bent SAS, Berg T, Karst U, Sperling M, Rustemeyer T. Allergic reaction to a green tattoo with nickel as a possible allergen. *Contact Dermatitis*. 2019;81(1):64–6.
117. Schreiber I, Hesse B, Seim C, Castillo-Michel H, Villanova J, Laux P, et al. Synchrotron-based  $\nu$ -XRF mapping and  $\mu$ -FTIR microscopy enable to look into the fate and effects of tattoo pigments in human skin. *Sci Rep-UK*. 2017;7(1):11395.
118. Darvin ME, Schleusener J, Parenz F, Seidel O, Krafft C, Popp J, et al. Confocal Raman microscopy combined with optical clearing for identification of inks in multicolored tattooed skin in vivo. *Analyst*. 2018;143(20):4990–9.
119. Schreiber I, Eschner L-M, Luch A. Matrix-assisted laser desorption/ionization tandem mass spectrometry for identification of organic tattoo pigments in inks and tissue samples. *Analyst*. 2018;143(16):3941–50.
120. Sadura F, Wróbel MS, Karpienko K. Colored tattoo ink screening method with optical tissue phantoms and Raman spectroscopy. *Materials (Basel)*. 2021;14(12):3147.
121. Wróbel MS, Kim JH, Raj P, Barman I, Smulko J. Utilizing pulse dynamics for non-invasive Raman spectroscopy of blood analytes. *Biosens Bioelectron*. 2021;180:113115.
122. Wróbel MS, Popov AP, Bykov AV, Tuchin VV, Jędrzejewska-Szczerska M. Nanoparticle-free tissue-mimicking phantoms with intrinsic scattering. *Biomed Opt Express*. 2016;7(6):2088–94.

**How to cite this article:** Giulbudagian M, Battisini B, Bäuml W, Blass Rico AM, Bocca B, Brungs C, et al. Lessons learned in a decade: Medical-toxicological view of tattooing. *J Eur Acad Dermatol Venereol*. 2024;00:1–13. <https://doi.org/10.1111/jdv.20072>