

Proximal fibular osteotomy as a treatment for degenerative meniscal extrusion

P. Łuczkiwicz^a, K. Daszkiewicz^{b,*}, J. Dzierżanowski^c, W. Witkowski^b

^a Second Clinic of Orthopaedics and Kinetic Organ Traumatology, Medical University of Gdansk, Gdansk, Poland

^b Department of Mechanics of Materials and Structures, Faculty of Civil and Environmental Engineering, Gdansk University of Technology, Gdansk, Poland

^c Department of Neurosurgery, Medical University of Gdansk, Gdansk, Poland

ARTICLE INFO

Keywords:

Proximal fibular osteotomy
Fibulectomy
Meniscal extrusion
Osteoarthritis
Meniscus

ABSTRACT

Meniscal extrusion treatment is a key focus area for research and clinical study of degenerative knee pathology. The contact forces between the meniscus and the bones cause external displacements of the meniscus that are resisted by the circumferential fibres. The main risk factors for the excessive deformation of the meniscus are meniscal root tears, disruption of the circumferential fibres, knee malalignment and high body mass index. Prior research has shown meniscal extrusion to be a crucial determinant of successful procedures in knee osteoarthritis treatment. The characteristics of medial knee osteoarthritis are an increase in varus malalignment and the load transferred through the medial compartment. This is associated with greatest reduction of the joint space width over the medial meniscus body and an increase in contact forces acting on the meniscus, which results in increased extrusion of the medial meniscal body. Relocating the meniscus in its anatomic position restores the correct distribution of contact force across the knee joint, and prevents destruction of the cartilage. Thus, clinical and biomechanical research focus on improving surgical techniques that allow for diminished meniscal extrusion. Proximal fibula osteotomy is a relatively new technique which involves the removal of a 10 mm piece of fibula, 4–10 cm from the fibular head. This technique has been shown to reduce the knee-lever arm, load transferred through the medial compartment and increase the medial joint space width. We hypothesise that proximal fibular osteotomy could be an effective, simple, and minimally invasive treatment for degenerative meniscal extrusion.

Introduction

Knee menisci are crescent-shaped fibrocartilaginous structures that play a crucial role in distributing mechanical loads on articular cartilage [1]. Change in the meniscus geometry and external shift of the meniscus (meniscal extrusion) decreases coverage of the tibial plateau, increases the load acting on the cartilage, and is associated with the progression of osteoarthritis, cartilage loss, and bone marrow lesions [2,3]. In the clinical point of view, meniscal body displacement beyond the peripheral tibial plateau margin, greater than 3 mm, is described as meniscal extrusion [4]. The measurement of meniscal displacement is performed on the MRI, in accordance with the techniques proposed by Hada et al., in the coronal plane at the posterior border of the medial collateral ligament [5]. Recently, an automated techniques have been proposed to

fully quantify meniscal extrusion in three dimensions [6]. The main factors that contribute to meniscal extrusion are radial meniscal tear, disruption of the meniscus root attachment [7,8], varus alignment of the lower limb [9], and joint space narrowing in the course of knee osteoarthritis [10,11]. Meniscal extrusion in osteoarthritic knee joints is a consequence of both degenerative meniscal tear and cartilage defects with joint space narrowing. Moreover, meniscal extrusion is more strongly correlated with joint space narrowing when compared with meniscal tears [11,12]. Therefore, meniscal repair and other meniscal procedures such as partial meniscectomy or meniscal centralization should be cautiously considered in osteoarthritis or cartilage defects [13,14]. Satisfactory clinical results were reported after medial opening wedge high tibial osteotomy (HTO) for degenerative meniscal extrusion [15,16]. However, this procedure has some disadvantages, including the

Abbreviations: HTO, high tibial osteotomy; OA, osteoarthritis; KAM, knee adduction moment; PFO, proximal fibular osteotomy.

* Corresponding author at: Gdańsk University of Technology, Faculty of Civil and Environmental Engineering, 80-233 Gdańsk, Gabriela Narutowicza 11/12, Poland.

E-mail address: kardasz@pg.edu.pl (K. Daszkiewicz).

<https://doi.org/10.1016/j.mehy.2023.111119>

Received 25 February 2023; Received in revised form 4 July 2023; Accepted 9 July 2023

Available online 13 July 2023

0306-9877/© 2023 The Author(s). Published by Elsevier Ltd. This is an open access article under the CC BY license (<http://creativecommons.org/licenses/by/4.0/>).

delay of full-weight bearing, risk of bone nonunion, peroneal nerve paralysis, surgical wound infection [17,18]. Thus, new, less invasive methods for treatment of degenerative meniscal extrusion still need development.

The hypothesis

Proximal fibular osteotomy could be an effective treatment for degenerative meniscal extrusion.

Evaluation of the hypothesis

Biomechanics of the meniscus and meniscal extrusion

The menisci are fibrocartilage structures located between femoral and tibial condyles. They are composed of 70% water, 22% collagen, and a very small proportion of proteoglycan and elastin [19]. The roles of the meniscus are load transmission, shock absorption, and redistribution of the contact force across the knee joint. These functions are determined by the material structure and geometry of the meniscus. Histologically, the menisci consist of extracellular matrix and cells. Extracellular matrix consists of 75% of collagen fibres, oriented in circumferential, radial, and oblique directions [20]. The circumferential

fibres function mechanically to convert compressive load into hoop stress. The radial and oblique fibres provide structural rigidity and ability to resist the large hoop stresses [21]. Disruption of the circumferential fibres that counteract the external displacements of the meniscus may result in extrusion of the meniscus [22]. In the stance position, approximately 40–60% of the load that acts on the knee joint is transmitted through the meniscus [23]. Consequently, forces acting on the meniscus are proportional to the ground reaction force, and a high body mass index is considered a risk factor for posterior horn root tear [24] and meniscal extrusion [25].

The geometry of the meniscus has greater influence on the stresses transmitted through the meniscus than its material properties [26]. In each cross-section of the meniscus, the contact forces N_{fem} , N_{tib} , between the meniscus and the bones generate a horizontal resultant force F_e that acts on the meniscus in a radial direction (Fig. 1a). The resultant force F_e is proportional to the slope angle of the meniscus in the cross-section plane, and causes the meniscus to deform radially, which may result in meniscal extrusion [27]. Excessive deformation of the meniscus is resisted by the circumferential fibres and the meniscotibial ligament attached to the meniscal body. Hence, any disruption or lesion of the meniscotibial ligament is a risk factor for isolated meniscal extrusion [28]. Analysis of the extrusion force acting on the meniscus showed a correlation between meniscal external shift in the coronal plane and the

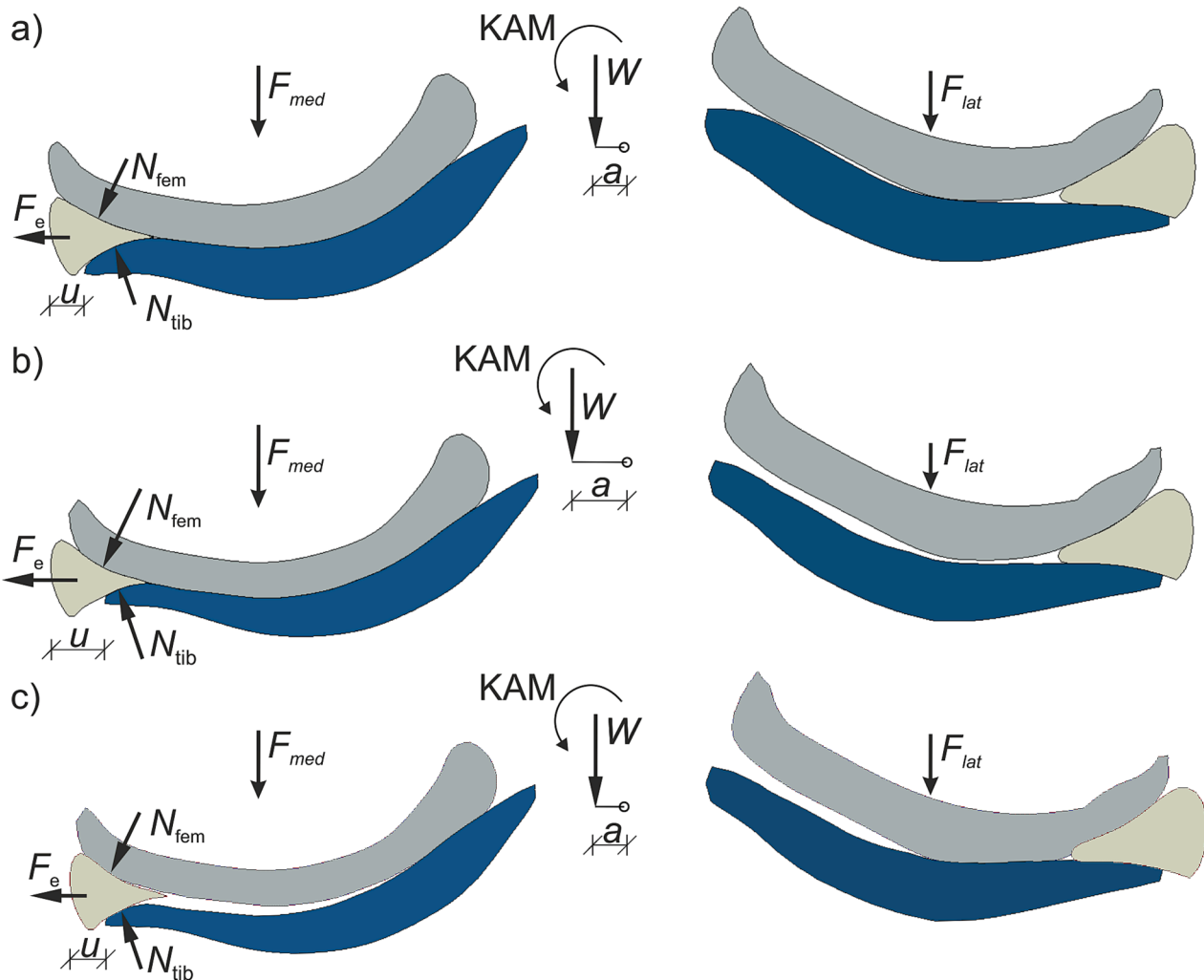


Fig. 1. Forces acting on the knee joint and the medial meniscus in a coronal cross sectional plane: (a) healthy knee joint; (b) osteoarthritic knee joint; (c) predicted state of knee joint after PFO. W , body weight transmitted through the tibiofemoral joint; a , knee lever arm; KAM, knee adduction moment; F_{med} , force in the medial compartment; F_{lat} , force in the lateral compartment; N_{fem} , contact force from femoral condyle; N_{tib} , contact force from tibial plateau; F_e , resultant (extrusion) force; u , external shift of the meniscus (meniscal extrusion).

slope angle of the meniscal midbody [29]. The finite element study [30] confirmed that the risk of meniscal extrusion increases with the meniscus height and thus the slope angle [27]. The medio-lateral relative bone translation may also influence meniscal external shift [30,31].

Biomechanics of the meniscus in osteoarthritic knee joints

Medial knee osteoarthritis (OA) causes a nonuniform reduction in the thickness of the articular cartilage [32], and decrease in the compressive stiffness of soft tissues [33,34]. The characteristics of medial knee OA are joint space narrowing and greater reduction in cartilage thickness in the medial compartment [35]. This is associated with an increase in varus malalignment, which increases knee adduction moment (KAM) and the load transferred through the medial compartment F_{med} [36]. An increase in contact forces N_{fem} , N_{tib} , and extrusion force F_e acting on the meniscus (Fig. 1b) was observed especially in the medial meniscus body due to greatest reduction of the joint space width in this region. This mechanism caused a 57% increase in the medial shift of the medial meniscus midbody in the stance phase of the gait cycle, and a significant increase in the maximum hoop stress in the posterior horn [37]. An increased load on the circumferential fibres coupled with degenerative changes in the collagen bundles may result in microscopic damage and lesions, leading to meniscal extrusion. In contrast, a decrease in the compressive stiffness of menisci and cartilage resulted in decrease of medial shift of the medial meniscus midbody due to twofold greater reduction in the meniscal body width than in an intact knee [37]. Crema et al., evaluating 2131 knees with or at risk of osteoarthritis using validated scores, found that varus malalignment and cartilage damage are associated with meniscal extrusion [38]. The above results confirm that changes in geometry of articular cartilage, causing varus malalignment, increase medial meniscal extrusion in the medial knee OA [31,37–39].

Biomechanics of proximal fibular osteotomy

Proximal fibula osteotomy (PFO) is a relatively new technique in the management of medial compartment knee osteoarthritis. It involves the removal of a 10 mm piece of fibula, 4–10 cm from the fibular head [40–42]. In 2014, Yazdi et al. revealed that PFO has a protective effect on the knee joint by reducing the pressure over the medial compartment [43]. One year later, Yang et al. demonstrated the effectiveness of upper partial fibulectomy for patients with moderate radiographic medial knee osteoarthritis [42]. In further studies, many authors confirmed improvement in long-term clinical outcomes after PFO surgery [44–46]. Nie et al., analysing biomechanical properties of the knee in response to upper partial fibulectomy, revealed that PFO caused the transfer of load from the medial to the lateral tibia by increasing hip-knee-ankle angle from 177.12 ± 2.16 to 178.36 ± 1.92 , and a 19.2 % reduction of the knee lever arm [40]. Significant reduction of the stresses in the medial compartment of the knee joint after PFO was observed in finite element study of 10 patients [47]. The mechanism by which upper partial fibulectomy improved the hip-knee-ankle angle and reduced the knee-lever arm is still not sufficiently elucidated. Qin et al. revealed that clinical improvement after PFO is proportional to the amount of distalization of the proximal fibula [48]. They conceptualized that after PFO, the soleus and peroneus longus pulled the fibular head down distally, creating traction in the lateral compartment and valgus rotation. Dong et al. presented another theory stating that removal of the proximal fibula resulted in less support of the lateral condyle and greater settlement of the lateral side of the tibial plateau [49]. Although the mechanism of these changes following a PFO is not clear, this procedure undoubtedly reduces knee lever arm and adduction moment, rebalances the biceps-proximal fibula-peroneus longus complex, and reduces the forces over the medial meniscus body (Fig. 1c). Consequently, we hypothesized that increase in medial joint space width after PFO would diminish meniscal extrusion.

Consequences of the hypothesis and discussion

Meniscal extrusion is found in several knee disorders, among which meniscal tears and OA are prominent. Thus, treatment is primarily based on the cause of meniscal external shift [8]. Although direct repair a detached meniscotibial ligament, meniscus root repair and restoration of the meniscus to its native position on the tibial plateau have been well established in the treatment of traumatic meniscal tears and meniscal extrusion, none of these methods have long-term follow-up data evaluating efficacy [15,50–52]. Moreover, systematic review showed that reduction of meniscal extrusion was obtained in only 56% of patients [53]. Degenerative meniscal extrusion is usually a chronic process that is part of the progression of knee joint arthrosis. Conservative treatment with chondroitin sulfate, glucosamine, physical therapy or lateral wedge insoles may lead to alleviation of knee pain with minimal influence on meniscal extrusion [54–56]. In past decades, partial meniscectomy was considered as one of the options for treatment of meniscal tears. In 1948 Fairbank, for the first time described the radiological changes occurring after meniscectomy [57]. Nowadays it is well established that meniscectomy leads to cartilage degeneration and osteoarthritis, even after a small resection of the meniscus [58]. Clinically, in the case of degenerative medial meniscus lesions, large medial meniscal extrusion and varus alignment are poor prognostic factors for arthroscopic partial meniscectomy [59].

The medial meniscal extrusion force has been shown to be correlated with the KAM and meniscal slope angle [29,60]. Solomonow-Awnon et al. reported that KAM depends on the value of ground reaction force and the distance from the centre of the knee joint to the centre of pressure of the foot (knee lever arm) [61]. Assuming that ground reaction force is constant, the only way to diminish the value of extrusion force and meniscal extrusion is to reduce the knee lever arm or meniscal slope angle. Astur et al. verified this hypothesis by performing 66 medial tibial opening osteotomies, with medial meniscal extrusion greater than 3 mm, medial compartment knee pain and varus knee malalignment [17]. Measurements of meniscal extrusion, pre- and postoperatively, were made on MRI coronal view. They found out that at 6 weeks, postoperatively, meniscal extrusion had decreased from 3.9 ± 0.6 mm to 0.9 ± 0.5 mm. Similarly, Lee et al. observed a decrease in medial meniscal extrusion from 3.6 ± 1.8 mm to 2.8 ± 1.5 mm after medial opening wedge HTO [62]. In addition, they found that a reduction in medial meniscal extrusion was correlated with preoperative varus alignment. Although medial opening wedge HTO is a common procedure for reduction of the knee lever arm, it has some disadvantages, including increased risk of nonunion and delayed union, peroneal nerve paralysis, surgical wound infection, deep vein thrombosis, vascular injury, and compartment syndrome [18,19].

Zou et al., in a prospective comparison study of 40 patients with PFO, and 52 patients with HTO for unilateral varus knee osteoarthritis, found significantly decreased operation time, perioperative bleeding, time to full weight-bearing, pain VAS score, and complications in the PFO group [63]. Wu et al. reported in meta-analysis of ten studies that PFO treatment has the lower complications rate (7.7%) than HTO treatment (11%) [64]. The most serious complications include transient peroneal nerve injury, which resolved within 2–18 months, and peroneal nerve palsy [45]. Based on the above data, one can hypothesise that PFO may be considered a valuable, inexpensive, and safe option for meniscal extrusion treatment. The main advantage of this procedure is minimal surgical trauma, low costs of operation, little postoperative pain, fast rehabilitation, early weight-bearing and low rate of complications. Certainly, PFO is more invasive than pharmacological treatment. On the other hand, PFO treatment resulted in more favorable outcomes with less pain and better knee functions than other methods [45]. The main disadvantage of this procedure is a relatively small degree of hip-knee-ankle angle improvement. Therefore, the proposed indications for PFO surgery are degenerative meniscal extrusion with medial compartment knee pain and varus knee malalignment less than 5 degree [44]. The

literature presents no evidence for the direct influence of PFO on meniscal extrusion. The initial Author's observations allow to confirm the hypothesis presented above although further clinical trials are necessary to assess the influence of PFO on the amount of meniscal extrusion.

Funding

This research received no specific grant from any funding agency in the public, commercial, or not-for-profit sectors.

Declaration of Competing Interest

The authors declare that they have no known competing financial interests or personal relationships that could have appeared to influence the work reported in this paper.

References

- Walker PS, Erkman MJ. The role of the menisci in force transmission across the knee. *Clin Orthop Relat Res* 1975;109:184–92. <https://doi.org/10.1097/00003086-197506000-00027>.
- Roemer FW, Zhang Y, Niu J, Lynch JA, Crema MD, Marra MD, et al. Tibiofemoral joint osteoarthritis: Risk factors for MR-depicted fast cartilage loss over a 30-month period in the multicenter osteoarthritis study. *Radiology* 2009;252(3):772–80.
- Roemer FW, Kwok CK, Hannon MJ, Green SM, Jakicic JM, Boudreau R, et al. Risk factors for magnetic resonance imaging-detected patellofemoral and tibiofemoral cartilage loss during a six-month period: The Joints on Glucosamine study. *Arthritis Rheum* 2012;64(6):1888–98.
- Costa CR, Morrison WB, Carrino JA. Medial Meniscus Extrusion on Knee MRI: Is Extent Associated with Severity of Degeneration or Type of Tear? *AJR Am J Roentgenol* 2004;183:17–23.
- Hada S, Ishijima M, Kaneko H, Kinoshita M, Liu L, Sadatsuki R, et al. Association of medial meniscal extrusion with medial tibial osteophyte distance detected by T2 mapping MRI in patients with early-stage knee osteoarthritis. *Arthritis Res Ther* 2017;19(1). <https://doi.org/10.1186/s13075-017-1411-0>.
- Bloecker K, Wirth W, Guermazi A, Hitzl W, Hunter DJ, Eckstein F. Longitudinal change in quantitative meniscus measurements in knee osteoarthritis — data from the Osteoarthritis Initiative. *Eur Radiol* 2015;25:2960–8. <https://doi.org/10.1007/s00330-015-3710-7>.
- Lerer DB, Umans HR, Xu MX, Jones MH. The role of meniscal root pathology and radial meniscal tear in medial meniscal extrusion. *Skeletal Radiol* 2004;33:569–74. <https://doi.org/10.1007/s00256-004-0761-2>.
- Gajjar SM, Solanki KP, Shanmugasundaram S, Kambhampati SBS. Meniscal Extrusion: A Narrative Review. *Orthop J Sport Med* 2021;9:1–10. <https://doi.org/10.1177/23259671211043797>.
- Sugita T, Kawamata T, Ohnuma M, Yoshizumi Y, Sato K. Radial displacement of the medial meniscus in varus osteoarthritis of the knee. *Clin Orthop Relat Res* 2001;387:171–7. <https://doi.org/10.1097/00003086-200106000-00023>.
- Gale DR, Chaisson CE, Totterman SMS, Schwartz RK, Gale ME, Felson D. Meniscal subluxation: Association with osteoarthritis and joint space narrowing. *Osteoarthr Cartil* 1999;7:526–32. <https://doi.org/10.1053/joca.1999.0256>.
- Hunter DJ, Zhang YQ, Tu X, LaValley M, Niu JB, Amin S, et al. Change in joint space width: Hyaline articular cartilage loss or alteration in meniscus? *Arthritis Rheum* 2006;54(8):2488–95.
- Adams JG, McaLindon T, Dimasi M, Carey J, Eustace S. Contribution of meniscal extrusion and cartilage loss to joint space narrowing in osteoarthritis. *Clin Radiol* 1999;54(8):502–6.
- Lee D-H, Lee B-S, Kim J-M, Yang K-S, Cha E-J, Park J-H, et al. Predictors of degenerative medial meniscus extrusion: Radial component and knee osteoarthritis. *Knee Surgery, Sport Traumatol Arthrosc* 2011;19(2):222–9.
- Koga H, Muneta T, Yagishita K, Watanabe T, Mochizuki T, Horie M, et al. Arthroscopic Centralization of an Extruded Lateral Meniscus. *Arthrosc Tech* 2012;1:e209–12. doi:10.1016/j.eats.2012.08.001.
- Koga H, Muneta T, Watanabe T, Mochizuki T, Horie M, Nakamura T, et al. Two-Year Outcomes After Arthroscopic Lateral Meniscus Centralization. *Arthrosc J Arthrosc Relat Surg* 2016;32(10):2000–8.
- Choi HG, Kang YS, Kim JS, Lee HS, Lee YS. Meniscal and Cartilage Changes on Serial MRI After Medial Opening-Wedge High Tibial Osteotomy. *Orthop J Sport Med* 2021;9:1–9. <https://doi.org/10.1177/23259671211047904>.
- Astur DC, Novaretti JV, Gomes ML, Rodrigues AG, Kaleka CC, Cavalcante ELB, et al. Medial Opening Wedge High Tibial Osteotomy Decreases Medial Meniscal Extrusion and Improves Clinical Outcomes and Return to Activity. *Orthop J Sport Med* 2020;8:1–5. doi:10.1177/2325967120913531.
- Sprengrer TR, Doerzbacher JF. Tibial osteotomy for the treatment of varus gonarthrosis. Survival and failure analysis to twenty-two years. *J Bone Joint Surg Am* 2003;85(3):469–74.
- W-Dahl A, Robertsson O, Lidgren L. Surgery for knee osteoarthritis in younger patients. *Acta Orthop* 2010;81(2):161–4.
- McDevitt CA, Webber RJ. The ultrastructure and biochemistry of meniscal cartilage. *Clin Orthop Relat Res* 1990;252:8–18. <https://doi.org/10.1097/00003086-199003000-00003>.
- Fithian DC, Kelly MA, Mow VC. Material properties and structure-function relationships in the menisci. *Clin Orthop Relat Res* 1990;252:19–31.
- Allen AA, Caldwell GL, Fu FH. Anatomy and biomechanics of the meniscus. *Oper Tech Orthop* 1995;5(1):2–9.
- Walker PS, Arno S, Bell C, Salvadore G, Borukhov I, Oh C. Function of the medial meniscus in force transmission and stability. *J Biomech* 2015;48:1383–8. <https://doi.org/10.1016/j.jbiomech.2015.02.055>.
- Hwang B-Y, Kim S-J, Lee S-W, Lee H-E, Lee C-K, Hunter DJ, et al. Risk factors for medial meniscus posterior root tear. *Am J Sports Med* 2012;40(7):1606–10.
- Achtlich A, Petersen W, Willinger L, Sauter A, Rasper M, Wörtler K, et al. Medial meniscus extrusion increases with age and BMI and is depending on different loading conditions. *Knee Surgery, Sport Traumatol Arthrosc* 2018;26(8):2282–8.
- Meakin JR, Shrive NG, Frank CB, Hart DA. Finite element analysis of the meniscus: The influence of geometry and material properties on its behaviour. *Knee* 2003;10:33–41. [https://doi.org/10.1016/S0968-0160\(02\)00106-0](https://doi.org/10.1016/S0968-0160(02)00106-0).
- Luczkiewicz P, Daszkiewicz K, Chróścielewski J, Witkowski W, Kuik L. High meniscal slope angle as a risk factor for meniscal allograft extrusion. *Med Hypotheses* 2017;101:48–51. <https://doi.org/10.1016/j.mehy.2017.02.003>.
- Krych AJ, Bernard CD, Leland DP, Camp CL, Johnson AC, Finnoff JT, et al. Isolated meniscus extrusion associated with meniscotibial ligament abnormality. *Knee Surgery, Sport Traumatol Arthrosc* 2020;28(11):3599–605.
- Luczkiewicz P, Daszkiewicz K, Witkowski W, Chróścielewski J, Zarzycki W. Influence of meniscus shape in the cross sectional plane on the knee contact mechanics. *J Biomech* 2015;48:1356–63. <https://doi.org/10.1016/j.jbiomech.2015.03.002>.
- Luczkiewicz P, Daszkiewicz K, Witkowski W, Chróścielewski J, Ferenc T, Baczkowski B, et al. The influence of a change in the meniscus cross-sectional shape on the medio-lateral translation of the knee joint and meniscal extrusion. *PLoS One* 2018;13(2):e0193020.
- Luczkiewicz P, Daszkiewicz K, Chróścielewski J, Witkowski W, Winkowski PJ. The influence of articular cartilage thickness reduction on meniscus biomechanics. *PLoS One* 2016;11(12):e0167733.
- Favre J, Erhart-Hledik JC, Blazek K, Fasel B, Gold GE, Andriacchi TP. Anatomically Standardized Maps Reveal Distinct Patterns of Cartilage Thickness With Increasing Severity of Medial Compartment Knee Osteoarthritis. *J Orthop Res* 2017;35:2442–51. <https://doi.org/10.1002/jor.23548>.
- Robinson DL, Kersh ME, Walsh NC, Ackland DC, de Steiger RN, Pandy MG. Mechanical properties of normal and osteoarthritic human articular cartilage. *J Mech Behav Biomed Mater* 2016;61:96–109. <https://doi.org/10.1016/j.jmbm.2016.01.015>.
- Fischenich KM, Lewis J, Kindsfater KA, Bailey TS, Haut Donahue TL. Effects of degeneration on the compressive and tensile properties of human meniscus. *J Biomech* 2015;48:1407–11. <https://doi.org/10.1016/j.jbiomech.2015.02.042>.
- Muraki S, Akune T, En-yo Y, Yoshida M, Suzuki T, Yoshida H, et al. Joint space narrowing, body mass index, and knee pain: The ROAD study (OAC1839R1). *Osteoarthr Cartil* 2015;23(6):874–81.
- Kutzner I, Trepczynski A, Heller MO, Bergmann G, Hug F. Knee adduction moment and medial contact force-facts about their correlation during gait. *PLoS One* 2013;8(12):e81036.
- Daszkiewicz K, Luczkiewicz P. Biomechanics of the medial meniscus in the osteoarthritic knee joint. *PeerJ* 2021;9:e12509.
- Crema MD, Roemer FW, Felson DT, Englund M, Wang Ke, Jarraya M, et al. Factors associated with meniscal extrusion in knees with or at risk for osteoarthritis: The multicenter osteoarthritis study. *Radiology* 2012;264(2):494–503.
- Wenger A, Wirth W, Hudelmaier M, Noebauer-Huhmann I, Trattnig S, Bloecker K, et al. Meniscus body position, size, and shape in persons with and persons without radiographic knee osteoarthritis: Quantitative analyses of knee magnetic resonance images from the osteoarthritis initiative. *Arthritis Rheum* 2013;65(7):1804–11.
- Nie Y, Ma J, Huang ZeYu, Xu B, Tang S, Shen B, et al. Upper partial fibulectomy improves knee biomechanics and function and decreases knee pain of osteoarthritis: A pilot and biomechanical study. *J Biomech* 2018;71:22–9.
- Wang J, Lv H-Z, Chen W, Fan M-k, Li M, Zhang Y-z. Anatomical Adaptation of Fibula and its Mechanism of Proximal Partial Fibulectomy Associated with Medial Compartment Knee Osteoarthritis. *Orthop Surg* 2019;11(2):204–11.
- Yang Z-Y, Chen W, Li C-X, Wang J, Shao D-C, Hou Z-Y, et al. Medial Compartment Decompression by Fibular Osteotomy to Treat Medial Compartment Knee Osteoarthritis: A Pilot Study. *Orthopedics* 2015;38(12):e1110–4. <https://doi.org/10.3928/01477447-20151120-08>.
- Yazdi H, Mallakzadeh M, Mohtajeb M, Farshidfar SS, Baghery A, Givehchian B. The effect of partial fibulectomy on contact pressure of the knee: a cadaveric study. *Eur J Orthop Surg Traumatol* 2014;24:1285–9. <https://doi.org/10.1007/s00590-013-1381-0>.
- Chen G, Xu B, Xie J, Nie Y, Tang S, Ma J, et al. Comparison of Clinical and Biomechanical Outcomes between Partial Fibulectomy and Drug Conservative Treatment for Medial Knee Osteoarthritis. *Biomed Res Int* 2019;2019:4575424.
- Sugianto JA, Hadipranata T, Lazarus G, Amrullah AH. Proximal fibular osteotomy for the management of medial compartment knee osteoarthritis: A systematic review and meta-analysis. *Knee* 2021;28:169–85. <https://doi.org/10.1016/j.knee.2020.11.020>.
- Utomo DN, Mahyudin F, Wijaya AM, Widhiyanto L. Proximal fibula osteotomy as an alternative to TKA and HTO in late-stage varus type of knee osteoarthritis. *J Orthop* 2018;15:858–61. <https://doi.org/10.1016/j.jor.2018.08.014>.

- [47] Pan D, TianYe L, Peng Y, JingLi X, HongZhu L, HeRan Z, et al. Effects of proximal fibular osteotomy on stress changes in mild knee osteoarthritis with varus deformity: A finite element analysis. *J Orthop Surg Res* 2020;15(1):375. <https://doi.org/10.1186/s13018-020-01894-1>.
- [48] Qin Di, Chen W, Wang J, Lv H, Ma W, Dong T, et al. Mechanism and influencing factors of proximal fibular osteotomy for treatment of medial compartment knee osteoarthritis: A prospective study. *J Int Med Res* 2018;46(8):3114–23.
- [49] Dong T, Chen W, Zhang F, Yin B, Tian Y, Zhang Y. Radiographic measures of settlement phenomenon in patients with medial compartment knee osteoarthritis. *Clin Rheumatol* 2016;35:1573–8. <https://doi.org/10.1007/s10067-015-3146-0>.
- [50] Paletta GA, Crane DM, Konicek J, Piepenbrink M, Higgins LD, Milner JD, et al. Surgical Treatment of Meniscal Extrusion A Biomechanical Study on the Role of the Medial Meniscotibial Ligaments With Early Clinical Validation. *Orthop J Sport Med* 2020;8:2325967120936672. doi:10.1177/2325967120936672.
- [51] Debieux P, Jimenez AE, Novaretti JV, Kaleka CC, Kriscenski DE, Astur DC, et al. Medial meniscal extrusion greater than 4 mm reduces medial tibiofemoral compartment contact area: a biomechanical analysis of tibiofemoral contact area and pressures with varying amounts of meniscal extrusion. *Knee Surgery, Sport Traumatol Arthrosc* 2021;29(9):3124–32.
- [52] Chernchujit B, Agrawal S. Arthroscopic All-Inside Medial Meniscus Extrusion Reduction. *Arthrosc Tech* 2019;8:e495–501. <https://doi.org/10.1016/j.eats.2019.01.008>.
- [53] Feucht MJ, Kühle J, Bode G, Mehl J, Schmal H, Südkamp NP, et al. Arthroscopic Transtibial Pullout Repair for Posterior Medial Meniscus Root Tears: A Systematic Review of Clinical, Radiographic, and Second-Look Arthroscopic Results. *Arthrosc J Arthrosc Relat Surg* 2015;31(9):1808–16.
- [54] Yoshizuka H, Taniguchi T, Fukuta K, Mitsutake T, Honda S, Wang Y. Decrease in medial meniscal extrusion after physical therapy to improve knee pain and range of motion in patients with knee osteoarthritis: A retrospective study. *PLoS One* 2022;17(11):e0277628.
- [55] Makiev KG, Vasios IS, Georgoulas P, Tilkleridis K, Drosos G, Ververidis A. Clinical significance and management of meniscal extrusion in different knee pathologies: a comprehensive review of the literature and treatment algorithm. *Knee Surg Relat Res* 2022;34:35. <https://doi.org/10.1186/s43019-022-00163-1>.
- [56] Roubille C, Martel-Pelletier J, Abram F, Dorais M, Delorme P, Raynauld J-P, et al. Impact of disease treatments on the progression of knee osteoarthritis structural changes related to meniscal extrusion: Data from the OAI progression cohort. *Semin Arthritis Rheum* 2015;45(3):257–67.
- [57] Fairbank TJ. Knee joint changes after meniscectomy. *J Bone Jt Surg Br* 1948;30B:664–70. <https://doi.org/10.1302/0301-620x.30b4.664>.
- [58] Englund M, Roos EM, Lohmander LS. Impact of type of meniscal tear on radiographic and symptomatic knee osteoarthritis: A sixteen-year followup of meniscectomy with matched controls. *Arthritis Rheum* 2003;48:2178–87. <https://doi.org/10.1002/art.11088>.
- [59] Xu T, Xu L, Li X, Zhou Y. Large medial meniscus extrusion and varus are poor prognostic factors of arthroscopic partial meniscectomy for degenerative medial meniscus lesions. *J Orthop Surg Res* 2022;17:170. <https://doi.org/10.1186/s13018-022-03045-0>.
- [60] Erhart JC, Dyrby CO, D’Lima DD, Colwell CW, Andriacchi TP. Changes in in vivo knee loading with a variable-stiffness intervention shoe correlate with changes in the knee adduction moment. *J Orthop Res* 2010;28:1548–53. <https://doi.org/10.1002/jor.21183>.
- [61] Solomonow-Avnon D, Herman A, Wolf A. Mechanism of reducing knee adduction moment by shortening of the knee lever arm via medio-lateral manipulation of foot center of pressure: A pilot study. *J Biomech* 2019;83:143–9. <https://doi.org/10.1016/j.jbiomech.2018.11.041>.
- [62] Lee CH, Yang HY, Seon JK. Increased medial meniscus extrusion led to worse clinical outcomes after medial opening-wedge high tibial osteotomy. *Knee Surgery, Sport Traumatol Arthrosc* 2022;31:1614–22. <https://doi.org/10.1007/s00167-022-07148-3>.
- [63] Zou G, Lan W, Zeng Y, Xie J, Chen S, Qiu Y. Early clinical effect of proximal fibular osteotomy on knee osteoarthritis. *Biomed Res* 2017;28:9291–4.
- [64] Wu ZX, Ren WX, Wang ZQ. Proximal fibular osteotomy versus high tibial osteotomy for treating knee osteoarthritis: a systematic review and meta-analysis. *J Orthop Surg Res* 2022;17:470. <https://doi.org/10.1186/s13018-022-03299-8>.