POLSKI
PRZEGLĄD CHIRURGICZNY
2016, 88, 1, 7–14

10.1515/pjs-2016-0020

DE GRUYTER OPEN

SAFETY AND EFFICACY OF A VENTRALIGHT ST ECHO PS IMPLANT FOR A LAPAROSCOPIC VENTRAL HERNIA REPAIR – A PROSPECTIVE COHORT STUDY WITH A ONE-YEAR FOLLOW-UP

TARAS STETSKO[1], KAMIL BURY[4], IZABELA LUBOWIECKA[5], CZESŁAW SZYMCZAK[6], AGNIESZKA TOMASZEWSKA[5], MACIEJ ŚMIETAŃSKI[2,3]

Department of Surgery, District Hospital in Sławno[1]
Ordynator: dr n. med. *T. Stetsko*
Department of Surgery, District Hospital in Puck[2]
Ordynator: dr hab. *M. Śmietański*
2nd Department of Radiology, Medical University in Gdańsk[3]
Kierownik: dr hab. *E. Szurowska*
Department of Cardiac and Vascular Surgery, Medical University in Gdańsk[4]
Kierownik: prof. dr hab. *J. Rogowski*
Faculty of Civil and Environmental Engineering, University of Technology in Gdańsk[5]
Kierownik Katedry: prof. dr hab. inż. *P. Kłosowski*
Faculty of Ocean Engineering and Ship Technology, University of Technology in Gdańsk[6]
Kierownik Katedry: dr hab. inż. *L. Rowiński*

Laparoscopic ventral hernia repair has become popular technique. Every year, companies are introducing new products Thus, every mesh prior to introduction in clinical settings should be tested with a dedicated tacker to discover the proper fixation algorithm.

The aim of the study was to assess the safety and efficacy of the Ventralight ST implant with an ECHO positioning system and a dedicated fixation device, the SorbaFix stapler, in a prospective cohort of patients.

Material and methods. The study was a prospective single centre cohort study with a one-year follow-up period. Fifty-two patients received operations for a ventral hernia using a laparoscopic IPOM mesh – Ventralight ST ECHO PS. The size of the mesh and the fixation method were based on mathematical considerations. A recurrence of the hernia and pain after 1, 2 and 12 months were assessed as the primary endpoints.

Results. Two recurrences were noted, one in parastomal and one in a large incisional hernia. Pain was observed in 22 patients (41%) and mostly disappeared after 3 months (7%). The intensity of pain was low (VAS <2). However, 2 patients still experienced severe pain (VAS>6) until the end of the study.

Conclusion. The Ventralight ST Echo PS implant fixed with a Sorbafix stapler is a valuable and safe option for a laparoscopic ventral hernia repair. In our opinion, the implant could be used in all patients due to the hernia ring diameter. According to the mathematical models and clinical practice, we do not recommend this implant in orifices with a width larger than 10 cm.

Key words: ventral hernia, mesh, recurrence, pain, Ventralight ST

Laparoscopic ventral hernia repair has become a progressively popular technique. Good initial outcomes encourage many surgeons to use this technique to treat an ever increasing range of abdominal hernias that are both primary and incisional. A lot has been done to develop the ideal implant for intraperitoneal placement; however, an optimal fixation technique together with a mechanism of recurrence and pathophysiology of pain is yet to be thoroughly investigated. Every year, companies are introducing new or redesigned

products of different knitted structures and architecture. Due to factors such as a long period of time needed to conduct proper scientific research to assess the value of the implant and to finalise the follow-up, the paper may be published when the product is not on the market anymore. Few of the implants were on the market long enough to have valuable literature showing their usefulness and safety (1, 2). For example, the DualMesh made from ePTFE was well described in the literature, and the mesh behaviour and clinical outcomes were predictable for the next cohort group of patients. Examining the literature, we found that some cohort studies have been published examining a few other meshes, but there are still many implants with no clinical data. Until now, only RCTs comparing different meshes in clinical settings have been conducted (3).

In our previous studies, we found that mesh structure, anisotropic elasticity, ingrowth properties, and fixation technique may influence the outcome of the procedure. As a result of our mathematical modelling and experimental studies, we know that the algorithm for fixation is not constant and depends on the mesh and fascia elasticity, load-bearing capacity of the fixation device, dimensions of the hernia orifice and the overlap of the mesh (4, 5, 6). Thus, we believe that every mesh should be tested together with a dedicated tacker to find out the proper fixation algorithm prior to introduction to clinical settings. Publication of cohort observations seems to play a crucial role in post-marketing clinical surveillance of the product to demonstrate usefulness and safety. These studies are also extremely important in the absence of adequate guidelines and published consensus on mesh and fixation methods among the great diversity of expert opinions (7).

The aim of the study was to assess the safety and efficacy of the Ventralight ST implant with an ECHO positioning system and a dedicated fixation device, the SorbaFix stapler, in a prospective cohort of patients.

MATERIAL AND METHODS

Study design

The study was designed as a prospective single centre cohort study with a one-year follow up period. The study included all elective patients referred to a laparoscopic primary ventral or incisional hernia repairwho were older than 18 years of age, had a BMI ≤40 kg/m^2, had a hernia size less than 20 cm in length and 10 cm in width and who signed an informed consent form. We excluded patients who did not meet the established requirements, were unwilling to undergo laparoscopic procedures,who had an absolute contraindication to general anaesthesia (e.g., ASA IV patients) and who had a chronic disease treated with analgesics.

Five follow-up visits were planned for the study, including data collection during the hospital stay and at 7 days, 3 months, 6 months and 12 months after surgery. The primary outcome of the study was the recurrence rate and pain level across all time points. Technical details of the surgical procedure, the type of hernia according to the EHS classification and demographic data were collected to describe the treated group. Additionally, data on peri- and postoperative complications were collected including the incidence of infections, seroma formation and medical interventions in the follow-up period.

Numerical data were presented as medians with SD, and the demographical data were presented as percentages or were descriptively described (if the number was too small for statistical analysis). Microsoft Excel was used to collect and count the data.

Mesh and fixation device

Ventralight™ ST Echo PS Mesh (Davol Inc., Subsidiary of C. R. Bard, Inc., Warwick, RI) is a medium-weight monofilament polypropylene (PP) mesh co-knitted with an absorbable polyglycolic acid (PGA) fiber. The visceral side is coated with a chemically modified sodium hyaluronate (HA) and carboxymethylcellulose (CMC), with two key components of the Sepra® technology as its anti-adhesive barrier. The mesh was equipped with a specially designed balloon (ECHO Positioning System) supporting the mesh in its positioning and fixation (fig. 1). The balloon was removed at the end of the procedure along with the 5 mm trockar. SorbaFix™. Absorbable Fixation System, a dedicated stapler for ventral implant fixation.

MOST WIEDZY Downloaded from mostwiedzy.pl

Fig. Ventralight ST with positioning set

Preoperative evaluation

All patients received a complete physical examination and a standard laboratory workup prior to surgery. The anaesthesiological risk was classified according to the American Society of Anaesthesiologists' (ASA) classification.

Operative technique

Venous thromboembolism (VTE) prevention using a low-molecular-weight heparin (LMWH) was used. Preoperative single-dose antibiotic prophylaxis with 1 g of Cefazoline was administered at the time of anesthesia induction. In all cases, the LVIHR was performed by a one of four experienced surgeons, while also being supervised by a surgeon who experienced at least 100 LVIHR surgeries. After creating the pneumoperitoneum with a Veress needle at the left hypochondrium (Palmer's point), an 11 mm laparoscopic port for a 10 mm 30° telescope was introduced in the left flank at the same point. Two additional 5-mm ports were placed depending upon the location of the hernia defect. If the Ventralight ST mesh with an ECHO PS Positioning System was larger than 15 cm x 20 cm, we changed the 11 mm trocar to 13 mm. When necessary, adhesiolysis was cautiously performed using scissors and cautery, the hernia was exposed, and the surrounding area was prepared for mesh placement with a min 7 cm overlap in the craniocaudal (c-c) direction and 5 cm laterally (according to a mathematical model). Closure of the hernia defect was not attempted. The mesh, tailored to overlap with the hernia defect by at least 5 cm laterally an 7 cm cranio-caudally, was placed intraperitoneally and was fixed using either the "single crown" when the hernia orifice was not 5 cm or the "double-crown" technique when the orifices were between 5 and 10 cm. The distance between the fasteners ranged from 1 to 2 cm. If necessary, PDS (Ethicon Inc.) size 0 sutures (TAS) were allowed in the vertical line only (for hernia orifices larger than 7 cm in the c-c line).

No drains were allowed in the peritoneal cavity, except in the case of bleeding. The abdominal cavity was exsufflated, and the fascia was sutured at port sites exceeding 5 mm, followed by skin closure.

In the cases of non-reponable hernias when adhesiolysis was impossible without bowel damage, a small skin incision was made at the top of the hernia sac. The bowel was liberated via an open approach, the sac was excised, and the laparoscopy was performed after closing the peritoneum (at the level of the hernia ring).

Postoperative management

All patients received standard postoperative care, including mobilization and a return to normal diet as quickly as possible; a Truss was worn daily and nightly for 3 weeks and then daily for next 3 weeks. Analgesia in the postoperative period consisted of Metamizolum natricum 1 g or Paracetamol 1 g administered intravenously every six hours in the first 24 hours. If necessary, the study protocol allowed additional opioid and non-opioid analgesic agents to be administered for 3 consecutive days after the operation.

RESULTS

Participant flow

Enrolment began on 01.11.2012 and lasted until 01.02.2014. The study was conducted in the General Surgery Department in Ceynowa Hospital in Wejherowo, Poland. 53 patients were evaluated in the study. The baseline data, preoperative hernia characteristics, and intraoperative variables were noted and shown in tab. 1. Notably, 2 patients presented with

MOST WIEDZY Downloaded from mostwiedzy.pl

parastomal hernias (EHS type III). In 4 cases, an additional laparotomy was performed for the adhesiolysys.

Table 1. Patients baseline data

Characteristics	Treated group n=53
Gender (male/female)	22/31
Age (mean, SD, min, max)	72.5 (SD 12.44) 37 – 86
BMI (mean, sd)	36.50 (SD 6.36)
Cigarettes (y/n)	13/40
Work (no/light/heavy)	34/11/8
Hernia Type single/multifocal	20 / 5
Hernia diameter (mean, SD)	4.68 (SD 2.73)
Hernia length (mean, SD)	5.30 (SD 3.4)
Hernia width (mean, SD)	4.72 (SD 2.7)
Mesh area (mean, SD)	365.5 (SD 53.04)
Hernia Classification (EHS) M 1, 2, 3, 4, 5 L 1; 2; 3	0 / 9 / 25 / 8 / 1 4 / 5 2 (parastomal type III)
Hernia Incisional / primary	31 / 22
Hernia recurrent yes / no	8 / 45
ASA 1/2/3	15 / 34 / 4
Pain before surgery yes / no	18 / 35
Surgeon 1 / 2 / 3 / 4 / 5	48 / 2 / 1 / 1 / 1
Number of TAS 0 / 2	26 / 27
Intra-operative complications No / vessel injury / bowels injury Hybrid procedures	50 / 3 / 0 3
Analgesics yes / no	53 / 0

Recurrences

Two recurrences were noted, resulting in a recurrence rate of 3.77% after 12 months. Both were identified between the 3rd and 12th month after surgery.

In one case, recurrence occurred due to the rupture of the connection between the mesh and fascia. During the reoperation, the disconnection was visible in the upper lateral quadrant of the mesh on the left side. However, the primary hernia orifice width was measured to be 10 cm; thus, it should be classified as the border indication of the method. We suggest that the big width of the hernia orifice should receive additional TA sutures to make the connection safer (using even 4 additional lateral sutures) and prevent any disconnection.

The second case was a parastomal hernia. The recurrence was palpable after a few weeks, but the patient was still not reoperated on due to the leak of clinical symptoms and good alimentary tract function. In the controlled CT scan, the loop of the bowel (syphon) was visible under the skin, but the mesh was still not displaced. We stipulate that there is a possibility that the loop over the mesh was too long, and after the hernia sac shrank, the loop just persisted under the skin in a curved shape. In conclusion, we believe that this complication is technically a surgical failure and unrelated to the implant or the fixation algorithm itself.

Pain

The medians and SD values for the follow-up time periods are presented in tab. 2. The overall presence of pain was low, and patients were generally discharged without physical limitations. Seven days after surgery, the patients still expressed a little pain even with lower analgesic consumption. One month after surgery, 22 patients still reported pain, but the intensity of this filling was very low. Only 2 of those patients described pain levels higher than 3 (in 1-10 VAS), indicating limited daily activity. After 3 months, only 4 patients still suffered from pain, but the intensity limited normal functioning in only one case. After 12 months, pain was present in 2 patients, and they reported the intensity as VAS level 2. However, they judged this phenomenon to be

Table 2. Intensity of pain (MED and SD) and number of patients reporting pain during follow-up visits

	Discharge	7 days	1 month	3 month	6 month	12 month
MED	3	3	0	0	0	0
SD	1,367	1,829	1,356	0,820	0,477	0,477
Nr of patients with pain	50	46	22	4	2	2

MOST WIEDZY Downloaded from mostwiedzy.pl

irritating and even considered the decision to re-operate (which did not happen because the pain release of the next procedure could not be predicted). Notably, these 2 patients had high pain scores (VAS 6 and 7 after 7 days and over 3 after one month) throughout the whole post-operative period; the entrapment of nerves in the loops of TA sutures may be an explanation (fig. 2).

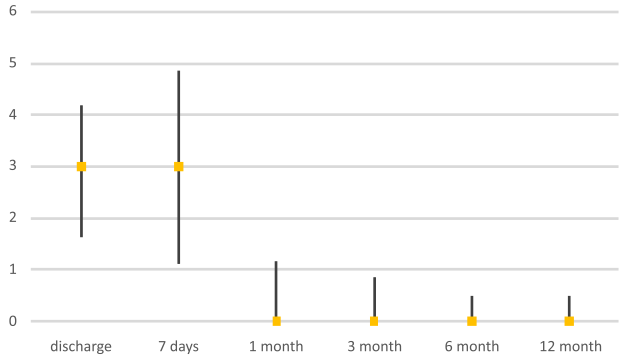

Fig 2. Pain reported during follow-up visits (MED and SD)

Other findings

The average operation time was 53.7 min. Excluding the parastomal cases, the average operation time would be less than 50 min (49,33). Twenty-nine patients were discharged on the first postoperative day. Six patients (including 2 parastomal cases) required a prolonged hospital stay over 4 days. Four cases of seroma were noted one month after surgery. Three of them resolved spontaneously. One needed a repeated aspiration and was still present after 12 months (an operation with a sac excision was considered in the next month). All of the patients returned to normal activity before the 1 month visit. No other complications were observed, and 100% of the patients judged their health status to be better than before the operation, even though 6 (11.3%) patients were not fully satisfied with the cosmetic effect.

DISCUSSION

While laparoscopic treatment of ventral hernias was introduced over 20 years ago, comparative results of treatments across various products have only been described. Cohort studies have been published, but there are still no Randomized Control Trials (RCTs) available in the literature comparing new meshes with anti-adhesive absorbable barriers and new absorbable fixation devices in humans in clinical settings. A meta-analysis published by Saurland (comparing open and laparoscopic techniques) showed great variation in the recurrence rates and pain levels in laparoscopic IPOM (8).

The recurrence rate for LVHIR varies in the available literature. Most authors believe that the number of recurrences is attributable to the type of fixation. Transfascial sutures usually have the lowest recurrence rate, and a single row of tacks usually have the highest recurrence rate. A double crown fixation technique (supported or not by TAS) has been described by many authors as a "gold standard" and shows a recurrence rate of about 5%. In the largest study by Heniford, the rate for double crown fixation with TAS was 4.7% (1). Similar outcomes have been found in the Cochrane meta-analysis. The total number of recurrences for the laparoscopic control group was 5%, but authors stated that figure was clearly lower than can be reasonably expected (8). In the recently published RCT by Hasan Eker, the cumulative recurrence rate for the group receiving laparoscopic treatment was 18 %, and the majority of recurrences were observed in the first year of follow-up (9).

As shown in our previous publications, recurrence occurs due to a fixation damage as a harmful consequence of the fixation overloading. According to our observations, three damage mechanisms are generally possible, including pulling the tacker out of the tissue, fracturing of the tacker, and rupturing the mesh at the fixation point. A load level applied to the fixation point depends not only on action on the abdominal wall (internal pressure, body movement etc.) and on spacing between the points but also on the mesh elasticity. The mesh can accumulate part of this force by using the elasticity to decrease the danger of fixation damage (6, 10). In our study, only two recurrences presented in the follow-up period; both could be explained using a technical or patient selection mistake. We strongly believe that this result could be achieved by selecting a proper fixation method for a used implant

MOST WIEDZY Downloaded from mostwiedzy.pl

based on the mechanical background of abdominal wall functioning and by employing simple algorithms into surgical practice. Those algorithms have been combined, creating HAL 2010.

The issue of high pain intensity after a laparoscopic hernia repair is a growing subject as the number of procedures performed yearly increases. The laparoscopic approach for an incisional and primary ventral hernia has gained popularity because of its low recurrence rate, short hospital stay, and low complication rate compared with an open repair (2, 8, 9, 11). However, as many as one-fourth of patients have been shown to have poor outcomes following a laparoscopic ventral hernia repair (12). In a study by Eriksen, participants complained that the pain was stronger (median VAS 78 mm) immediately after the procedure (i.e., laparoscopic cholecystectomy (median 40 mm) than later in the follow-up period (13).

Postoperative pain produced by fixation techniques could play an important role in deciding between sutures and tacks for mesh fixation. Sutures penetrate through the full thickness of the abdominal wall musculature and fascia. By contrast, the higher pain scores in the tacker group are hypothesized to be due to the screwing action of the sharp tips by which the tacks penetrate tissues, thereby causing compression and twisting of nerve fibres.

Those finding has inspired many researchers to explore the nature of the problem. Sutures running through a whole abdomen wall are considered to be the main source of pain. Carbonnel proved this finding by injecting topical anaesthetic around sutures, which decreased the pain (14). However, a randomised study by Wassenaar did not confirm those observations (15). On the other hand, Chelala followed by Bensal observed that upon decreasing intra-abdominal pressure by loosely tying the knots after fixing all of the sutures, the pain symptoms were significantly reduced (16, 17). In a study of 1223 patients, Sharma did not observe a relationship between pain symptoms and the implant fixation technique to the abdominal wallsix months after surgery (18). By contrast, Beldicompared suture versus tack mesh fixation in a randomized clinical trial and found that transfascial sutures were associated with more pain within the first 6 postoperative weeks (19). Another question would be whether the number of tackers influences the intensity of pain. This issue was a subject of research conducted by Schoenmaecker. He concluded that fewer tacks did not lead to less pain and that more tacks did not create more pain (20). The data obtained from previously published studies led us to the concept that there are a number of factors responsible for the increased perception of pain after LVIHR but that they appear to be associated with the forces applied to the fixings. Therefore, the pain could be reduced by an adequate number of tacks and elasticity of mesh. In our study, we used the previously described algorithm of fixation based on HAL 2010 software to minimize the number of tackers while still preserving the mesh-tissue junction. We found that the pain level in first 3 month was acceptable and does not influence the daily activity. We believe that the forces expressed on the tackers are reduced due to the elasticity of mesh and that pain mostly (over 90% of our patients) disappears after 3-6 months. We conclude that the mesh ingrowth distributes the forces on the whole implant, making the abdominal wall and the mesh one medium. Thus, the presence of tackers is not necessary after 3-6 months. This observation theoretically supports the idea of using of absorbable tackers for meshes with confirmed good ingrowth into the tissue.

To support this assumption, we searched the PubMed database and found only a few experimental and comparative studies mainly in animal models that compared meshes dedicated for an IPOM technique. Most of the articles showed similar results (21, 22, 23). One article described the mesh and tacker used in our cohort and compared it with Physiomesh and Securestrap (mesh and fixation system provided by Ethicon Inc.) in a porcine model (22). The authors evaluated the mesh contracture, adhesion characteristic, strength of tissue ingrowth, and host tissue response after a 14-day implantation period in a porcine model. The results favoured the Ventalight ST mesh in terms of adhesion formation (50% vs 30%) and adhesion coverage (1.2% ± 0.7% vs 6% ± 3.5%), while also significantly reducing inflammation (p=0.0001), fibrosis (p=0.0017), haemorrhage (p=0.0001), and angiogenesis (p=0.0032); the mesh also had significantly greater strength of tissue ingrowth (p=0.0003). Other findings were similar for both the mesh fixation device com-

MOST WIEDZY Downloaded from mostwiedzy.pl

binations and were comparable to the results of other studies with absorbable barrier meshes in animal models.

CONCLUSIONS

According to above presented data, we conclude that the use of a Ventralight ST Echo PS implant fixed with a Sorbafix stapler is a valuable and safe option for a ventral and incisional hernia repair using a laparoscopic approach. In our opinion, this approach could be used in all patients who have an indication for laparoscopy based on the hernia ring diameter. According to the mathematical models and clinical practice, we do not recommend this implant in orifices with widths larger than 10 cm.

REFERENCES

1. *Heniford BT, Park A, Ramshaw BJ, Voeller G:* Laparoscopic repair of ventral hernias: nine years' experience with 850 consecutive hernias. *Annals of Surg* 2003; 391-99.
2. *Kapischke M, Schulz T, Schipper T* et al.: Open versus laparoscopic incisional hernia repair: something different from a meta-analysis. *Surg Endosc* 2008; 22(10): 2251-60.
3. *Grubnik VV, Grubnik AV, Vorotyntseva KO:* Laparoscopic repair of incisional and ventral hernias with the new type of meshes: randomized control trial. Wideochirurgia i inne Tech mało inwazyjne = Videosurgery other miniinvasive Tech / Kwart Pod patronatem Sekc Wideochirurgii TChP oraz Sekc Chir Bariatrycznej TChP. 2014; 9(2): 145-51.
4. *Tomaszewska A, Lubowiecka I, Szymczak C* et al.: Physical and mathematical modelling of implant-fascia system in order to improve laparoscopic repair of ventral hernia. *Clin Biomech* 2013; 28: 743-51.
5. *Śmietański M, Bury K, Tomaszewska A* et al.: Biomechanics of the front abdominal wall as a potential factor leading to recurrence with laparoscopic ventral hernia repair. *Surg Endosc* 2012. p. 1461-67.
6. *Szymczak C, Lubowiecka I:* Modeling of the fascia-mesh system and sensitivity analysis of a junction force after a laparoscopic ventral hernia repair. *J Theor* 2010; 933–50.
7. *Pawlak M, Bury K, Śmietański M:* The management of abdominal wall hernias – in search of consensus. *Videosurg Miniinv* 2015; 10(1): 49-56.
8. *Sauerland S:* Laparoscopic versus open surgical techniques for ventral or incisional hernia repair. *Cohrane Database Syst Rev* 2011; (3).
9. *Eker H, Hansson B:* Laparoscopic vs Open Incisional Hernia Repair A Randomized Clinical Trial. *JAMA Surg* 2013; 148(3): 259-63.
10. *Lubowiecka I:* Mathematical modelling of implant in an operated hernia for estimation of the repair persistence. *Comput Methods Biomech Biomed Engin* 2013; 37-41.
11. *Rogmark P, Petersson U, Bringman S* et al.: Short-term outcomes for open and laparoscopic midline incisional hernia repair: a randomized multicenter controlled trial: the ProLOVE (prospective randomized trial on open versus laparoscopic operation of ventral eventrations) trial. *Ann Surg* 2013; 258(1): 37-45.
12. *Liang MK, Clapp M, Li LT* et al.: Patient Satisfaction, chronic pain, and functional status following laparoscopic ventral hernia repair. *World J Surg* 2013; 37(3): 530-37.
13. *Eriksen JR, Poornoroozy P, Jørgensen LN* et al.: Pain, quality of life and recovery after laparoscopic ventral hernia repair. *Hernia* 2009; 13(1): 13-21.
14. *Carbonell AM, Harold KL, Mahmutovic AJ* et al.: Local injection for the treatment of suture site pain after laparoscopic ventral hernia repair. *Am Surg* 2003; 69(8): 688-91; discussion 691-92.
15. *Wassenaar E, Schoenmaeckers E, Raymakers J* et al.: Mesh-fixation method and pain and quality of life after laparoscopic ventral or incisional hernia repair: a randomized trial of three fixation techniques. *Surg Endosc* 2010; 24(6): 1296-1302.
16. *Chelala E, Debardemaeker Y, Elias B* et al.: Eighty-five redo surgeries after 733 laparoscopic treatments for ventral and incisional hernia: adhesion and recurrence analysis. *Hernia* 2010; 14(2): 123-29.
17. *Bansal VK, Misra MC, Kumar S* et al.: A prospective randomized study comparing suture mesh fixation versus tacker mesh fixation for laparoscopic repair of incisional and ventral hernias. *Surg Endosc* 2011; 25(5): 1431-38.
18. *Sharma A, Mehrotra M, Khullar R* et al.: Laparoscopic ventral/incisional hernia repair: a single centre experience of 1,242 patients over a period of 13 years. *Hernia* 2011; 15(2): 131-39.
19. *Beldi G, Wagner M, Bruegger LE* et al.: Mesh shrinkage and pain in laparoscopic ventral hernia repair: a randomized clinical trial comparing suture versus tack mesh fixation. *Surg Endosc* 2011; 25(3): 749-55.
20. *Schoenmaeckers EJP, de Haas RJ, Stirler V* et al.: Impact of the number of tacks on postoperative pain in laparoscopic repair of ventral hernias: do

MOST WIEDZY Downloaded from mostwiedzy.pl

more tacks cause more pain? *Surg Endosc* 2012; 26(2): 357-60.
21. *Pascual G, Sotomayor S, Rodríguez M* et al.: Behaviour of a new composite mesh for the repair of full-thickness abdominal wall defects in a rabbit model. *PLoS One* 2013; 8(11): e80647.
22. *Deeken CR, Matthews BD:* Ventralight ST and SorbaFix versus Physiomesh and Securestrap in a porcine model. *JSLS* 2013; 17(4): 549-59.
23. *Winslow ER, Diaz S, Desai K* et al.: Laparoscopic incisional hernia repair in a porcine model: what do transfixion sutures add? *Surg Endosc* 2004; 18(3): 529-35.

Received: 21.01.2016 r.
Adress correspondence: 80-214 Gdańsk, ul. M. Smoluchowskiego 17
e-mail: smietana@gumed.edu.pl

MOST WIEDZY Downloaded from mostwiedzy.pl